

Report for the APSS Depuy

Synthes Spine Clinical Fellowship

2014

Fellow: Dr. Ming-Hsiao Hu, MD

Attending Doctor (Spine),
Clinical Instructor (Orthopaedics)
National Taiwan University Hospital
Taipei, Taiwan

Guide: Dr. Kuniyoshi Abumi, MD

1. Director of Sapporo Orthopaedic Hospital-Center for Spinal Disorders
2. Professor Emeritus, Hokkaido University

Duration: 27 Oct - 15 Nov 2014

Centre's visited:

Sapporo Orthopaedic Hospital-Center for Spinal Disorders & affiliated hospitals

- (1) Hokkaido University Graduate School of Medicine, Sapporo
- (2) Spinal Cord Injury Centre, Hokkaido Chuo Rosai Hospital, Bibai.
- (3) Hokkaido Orthopaedic Memorial Hospital, Sapporo
- (4) National Hospital Organization Hokkaido Medical Center, Sapporo
- (5) Eniwa Hospital, Eniwa

The Asia Pacific Orthopaedic Association (APOA) – Depuy Synthes Spine Clinical Fellowship 2014 took place from 27th October to 15th November 2014. I remembered that I was so excited and shouted with happiness at the day I received the acceptance letter from APOA committee this late August.

Actually, this is my third time at Hokkaido but it is totally different. I was a tourist in previous stay and this time, I have a chance to blend into local culture and daily life. Mostly important, of course, I can assist operation performed by Professor Abumi's team which is famous and talented.

I landed on 26th October via a direct flight from Taipei and checked in Hotel Met's Sapporo. It is a place just beside the campus of Hokkaido University and 3 minute walk to subway station, 2 station away from Sapporo JR station. I really appreciate Professor Abumi's kind arrangement. My fellowship course had started from 27th October.

Week 1 (27th Oct – 2nd Nov)

*** Academic schedule**

27th Oct (Mon) Eniwa Hospital

On the first day, I went to Eniwa, a east-southern city from Sapporo, 20 minute train distance. Dr. Shigenobu Sato received my arrival and then introduced me to scrub up in Dr. Abe's operation. My first case in Hokkaido was a 82-year-old female, a victim of

osteoporotic compression fracture, underwent kyphoplasty at L2 3 months ago. Cement dislodgement with vacuum phenomenon was found during follow-up. Because of no spinal canal compromise, Dr. Abe did posterior instrumentation from T10 to L3 with in situ fusion. He used cortical bone trajectory (CBT) technique in osteoporotic L1 and L2 to increase screw purchase power and save more motion segment.



Eniwa Hospital, Eniwa

28th Oct (Tue) Sapporo Orthopaedic H.

I met Professor Abumi and his international fellow, Dr. Dipak from Nepal, at his hospital at noon. There were two lumbar fixation surgeries that afternoon. First one was an old lady with adjacent degeneration of L1/2. We removed her old implants and extended instrumentation and fusion to symptomatic segment. The next one was a traditional PLIF surgery for L3/4 spondylolisthesis. I was surprised that Professor Abumi attended the whole operation from patient positioning to wound closure. Someone can hardly imagine he is almost 65 years.

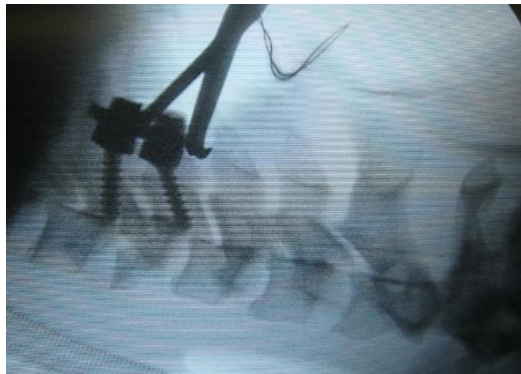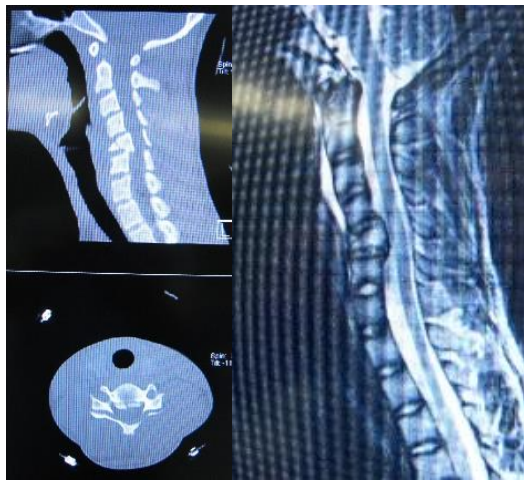


Dr. Dipak Maharjan from Nepal

29th Oct (Wed) Spinal Cord Injury Center, Bibai

Bibai is a neighboring city, approximately 60 km north-east of Sapporo, which is well connected by intercity trains (Sapporo to Asahikawa) Spinal Cord Injury Centre at Bibai is the only tertiary care center for spinal trauma in the island of Hokkaido. Here I met Dr. Suda, the vice president of this hospital, who was a hospitable doctor. He shared not only academic and surgical knowledge with me but different culture, life experience and his favorite, golf. There were 4 surgeries at that day and I scrubbed up in two of them. The second case was my first cervical spine surgery this time. He was a 14-year-old boy and suffered from diving injury 6 days before the surgery. Fracture subluxation over C5/6 was found. Due to small pedicle in this patient, Dr. Suda chose posterior instrumentation with lateral mass screw-rod system to save one more motion segment comparing to anterior surgery. The surgery was delicate, well - prepared preoperatively and confident.

It was very impressive to me. The day ended at ward discussion.

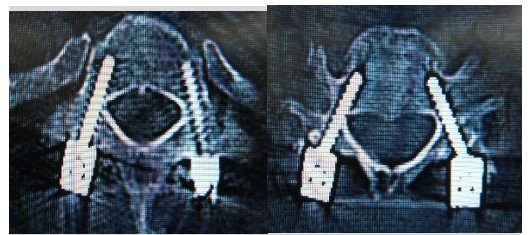
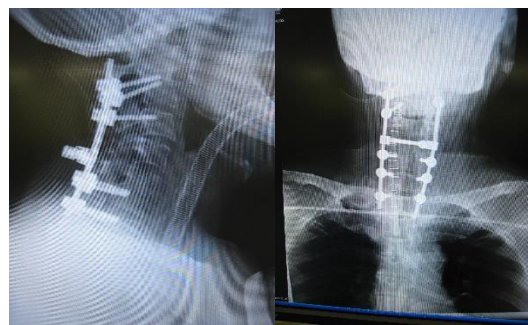
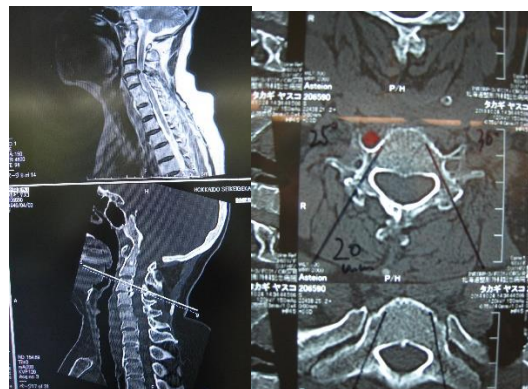


C5/6 traumatic fracture subluxation treated with lateral mass screw + rod system

30th Oct (Thu) Hokkaido Orthopaedic Memorial Hospital

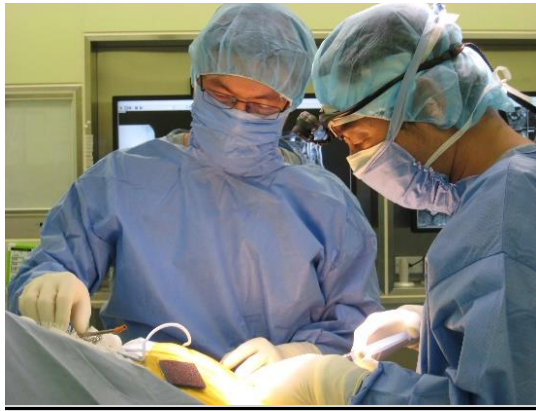Today I had a date with Dr. Oda in memorial Hospital. This hospital was the No. 1 private specialist hospital in Hokkaido. There were 15 orthopaedic surgeons, 4 anesthesiologists and 7 operation theatre. It is located at Minami Hiragishi Station, 20 minutes from my hotel. There were two cervical spine surgeries. First one was my mostly impressive surgery in first week, a rheumatoid patient who need a long instrumentation with fusion from C2 to T1. I joined the preoperative discussion

and planning, learned to figure out key points in image studies (such as anomaly of vertebral artery, screw direction and size and etc.) and scrubbed in. We set all pedicle screws and done laminectomy over C3-4-5. Dr. Oda and his assistant, Dr. Suzuki finished the whole operation within 2 hours. I was impressed and gained more confidence in my future cases. Second case was a multilevel cervical degenerative stenosis and Kurokawa laminoplasty from C3 to C6 was done. It was my first time to see Tomita saw and laminoplasty spacers.



Patient with rheumatoid arthritis, spontaneous fused C1/2 & C5/6, stenosis with instability

C3/4/5. Anomaly of right C4 vertebral artery was also found. C2-T1 posterior instrumentation with all pedicle screws done.



I assisted Dr. Ohshima to do cervical laminoplasty.



Hokkaido Orthopaedic Memorial Hospital

31st Oct (Fri) Hokkaido Orthopaedic Memorial Hospital

The only surgery I joined this day was Kurokawa laminoplasty for an OPLL patient. The day concluded with a traditional Japanese dinner hosted by Dr. Oda and Dr. Suzuki. It was a pleasant and wonderful meeting and we talked, drank, laughed and shared with each other. We found that there were lots of similar concepts of us and promised to cherish the friendship. I really thanked for wholehearted hospitality by Dr. Oda at the end of the day.



Dr. Suzuki, me and Dr. Oda

* Culture and Life

It is end of autumn during my first week in Sapporo. Hokkaido university is a very beautiful campus, especially in this season. Golden leaf avenue (ginkgo trees) gave me a great ovation. It was so romantic and fantastic while walking down the street. I heard that the leaves had been yellow just for 2-3 weeks and it announced that winter is coming.



Golden Ginkgo trees in Hokkaido University



Hokkaido University in autumn

Week 2 (3rd Nov – 9th Nov)

* Academic schedule

3rd Nov (Mon) National Holiday

4th Nov (Tue) Sapporo Orthopaedic H.

It started to snow in Sapporo mountain this early morning. Cool ! But today is sunny and warmer than last night. I met Professor Abumi and a new-visiting Indian doctor, Ashish Tomar, in his hospital at noon. There were 3 surgeries this afternoon and I scrubbed on in all of them. The first case is a 40-year-old male, suffering from early stage of myelopathy and mild left upper arm pain. The diagnosis was herniated disc with cervical stenosis over C5/6. The main point of this operation was not his disc but the posterior osteophyte. Abumi had used diamond burr well to remove whole osteophyte smoothly. The pre-op symptoms improved immediately after surgery, told by patient himself. The following cases were OPLL with cervical myelopathy and ruptured disc of L4/5. We performed laminoplasty and open discectomy for each of them. I admired professor Abumi very much because he still work so hard everyday and keeps enthusiasm and smile, always.


5th Nov (Wed) Spinal Cord Injury Center, Bibai

It was my second time to Bibai. It was warmer today. Dr. Suda had two operations today. First one was a 69-year-old male patient with degenerative spondylolisthesis at L4/5, and Suda

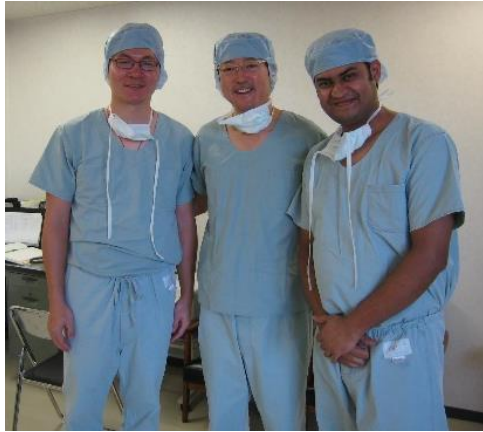performed TLIF as he usually did. The second case was a nurse with ruptured intervertebral disc at L5/S1 level, microdiscectomy was done smoothly. We attended case discussion in the afternoon. During the meeting, we reviewed the operated cases and shared experiences and opinion in some challenging cases. At the end of the day, Dr. Suda invited me to enjoy Japanese style dinner and wine with his team staff, Dr. Matsumoto, Dr. Yasui and Dr. Ushiku. Good wine, nice interaction and forever friendship, what a nice memory I have!



Spinal Cord Injury Center, Bibai



Case conference in Bibai



Dr. Suda (middle) and Dr. Ashish Tomar from India

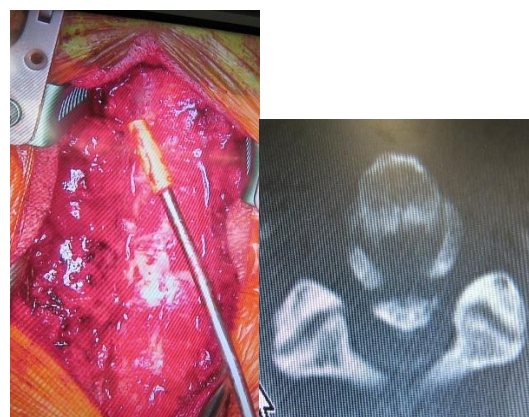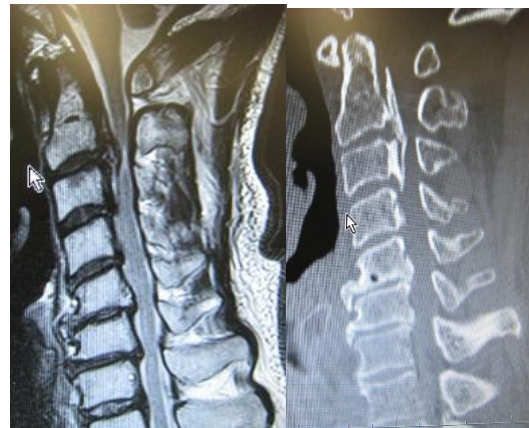6th Nov (Thu) Hokkaido University Hospital (am) + Sapporo Orthopaedics Hospital (pm)

It was my first time to visit Hokkaido University Hospital this morning. Dr. Masahiko Takahata, the new chief of spine group, welcomed me and took me to the operation theatre. Dr. Takahata is a gentle and cultivated doctor and has a great accomplishment in both clinical and basic studies. Surgery today was a 67-year-old male with OPLL over C2-7 and myelopathy. Dr. Takahata deep extensor muscle-preserving approach to finish laminoplasty. Post-op axial nuchal pain after cervical spine surgery have been an unsolved morbidity, especially when the surgery involved C2 and C7. This kind of approach preserved the muscle attachment and decreased muscle degeneration after operation. The results had been published last year. University hospital was equipped with high-quality video system, and it was a favor of visiting fellow to observe the operations.

We came back to Professor Abumi's hospital and the only case today was 88-year-old female with multi-level ossificated yellow ligament along thoraco-lumbar spine. The pathology is rare in Taiwan and I learned how to handle possible adhesion between calcified ligament and dura and avoid possible injury.



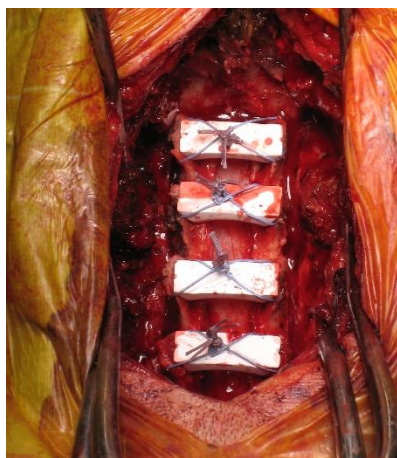
Hokkaido University Hospital



OPLL treated with muscle preserving approached laminoplasty by Dr. Takahata

7th Nov (Fri) Hokkaido Memorial Orthopaedic Hospital

This was a cold day and it snowed when I walked from subway station to the hospital. In the morning, Dr. Murota performed a microdiscectomy using Metronics Quadrant retractor system. I have been familiar with that because I use it for decompression and mini-TLIF surgery in Taiwan. We exchanged experiences with each other. In the afternoon, I scrubbed in a Kurokawa laminoplasty surgery. Dr. Murota used 4-mm high speed burr to split spinous process, instead of using Tomita saw. Spacers made up by hydroxypaptite were used in the final step of surgery. The day ended with a farewell dinner in Susukino, the most bustling area at night in Sapporo. The dinner was hosted by Dr. Oda and the doctors in memorial hospital, including Dr. Masanori Fujiya. Second party was held in a Japanese styled music bar, and we drank, dance and sang songs together. I really enjoyed it and thanked their kind hospitalization very much.



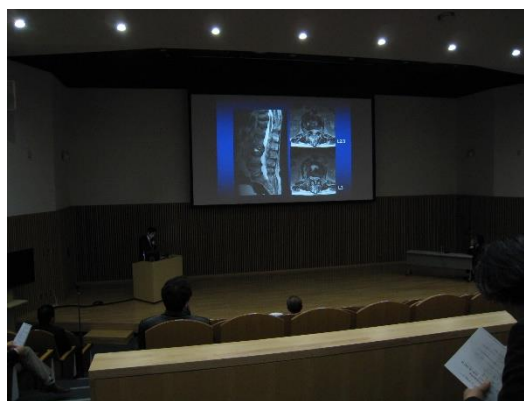Kurokawa laminoplasty with spacers



Dinner in Susukino. Dr. Fujiya (first from left) and Professor Abumi (second from right)

8th Nov (Sat) Hokkaido spinal disorders conference in Hokkaido University

In the afternoon, Professor Abumi took me to attend an academic meeting in university. Spine surgeons in Hokkaido joined together to share clinical cases and undergoing researches. It has been a very nice chance for me to see many famous spine surgeons in Hokkaido, such as Professor Manabu Ito and Hokkaido legend, professor Kaneda.



Hokkaido spinal disorders conference in Hokkaido University

* Culture and Life

In Hokkaido, especially in Sapporo,

you can easily see the words Dr. William Clark said, “Boys, be ambitious!” I had visited Hokkaido University and Hitsujigaoka Hill and there were portrait of Dr. Clark. It reminds people to keep working hard and not satisfied with what you are now. I think that it footnote this fellowship very well. After I come back to my country, I won’t forget those words. “Boys, be ambitious!”



Portrait of Dr. Clark in Hokkaido University and Hitsujigaoka Hill

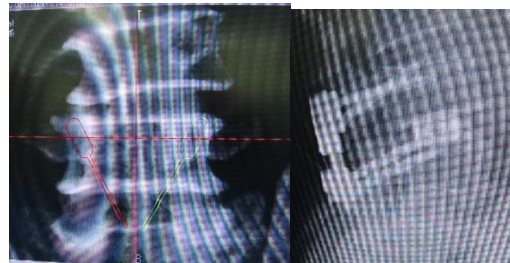
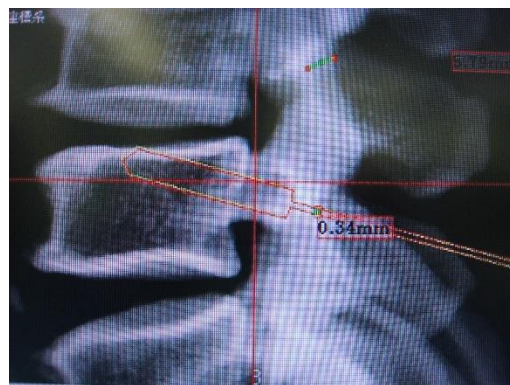
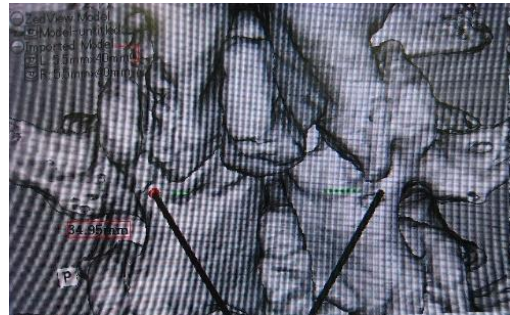Week 3 (10th Nov – 15th Nov)

* Academic schedule

10th Nov (Mon) Eniwa Hospital, Eniwa

It was my second time to visit Eniwa Hospital during this stay. There was only one case today: a 72-year-old gentleman with spondylolisthesis L3/4 and extra-foraminal disc herniation. Dr. Abe did PLIF for patient and used hybrid system of cortical bone trajectory screw (CBT) and pedicle screw. I was the first

assistant of this operation and made sure that I had confidence to insert correct CBT screws. Dr. Sato ate lunch with us and I thank for his kind arrangement very much.



Hybrid technique of CBT and traditional pedicle screw for L3/4 spondylolisthesis



Dr. Yuichiro Abe



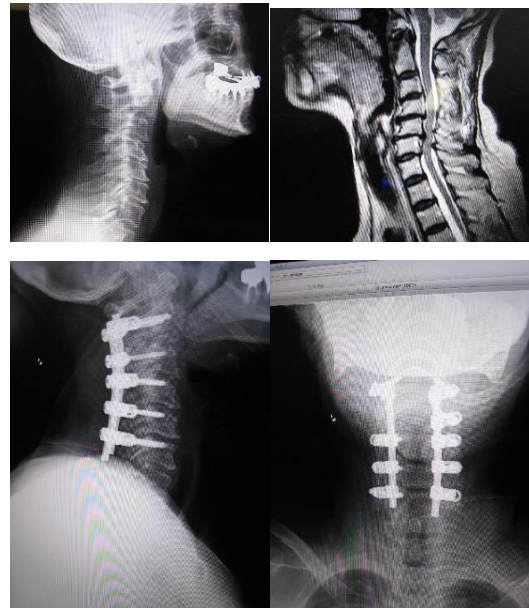
Dr. Shigenobu Sato

11th Nov (Tue) Hokkaido University Hospital (am) + Sapporo Orthopaedics Hospital (pm)

This was my second time to Hokkaido University Hospital this morning. They had always done scoliosis correction surgery on Tuesday. Today is a 27-year-old female with adolescent idiopathic scoliosis with rigid main thoracic curve (T6-L2, 66 degree with 53 degree with bending and 25 kg traction). The proximal thoracic curve was also structure curve, so surgical plan was posterior instrumentation with all pedicle screw and correction by derotation and distraction/compression methods. Multiple Ponte osteotomy was also performed due to sagittal imbalance and thoracic hypokyphosis. Dr. Hideki Sudo also gave us a perfect teaching. He showed several operative video to me, including anterior instrumentation for scoliosis correction (double rod system by Prof. Kaneda), posterior derotation method for AIS and posterolateral approach for thoracic OPPL.

We went back to Sapporo

Orthopaedic Hospital in the afternoon. Professor Abumi had a cervical kyphosis correction surgery using all pedicle screw from C2 to C6. It was usually exciting and enjoyable to observe Abumi inserting cervical pedicle screws. Dreams come true that I was his first assistant. From patient positioning, surgical approach and dissection, identify anatomic landmark and make the correct screw insertion. Professor taught us by steps and just did it to my face. What a precious experience! The final surgery today was PLIF for an isthmic spondylolisthesis over L5/S1. What an amazing day I had !



Posterior instrumentation with pedicle screw for cervical kyphosis by Prof. Abumi

12th Nov (Wed) Hokkaido Memorial Orthopaedic Hospital

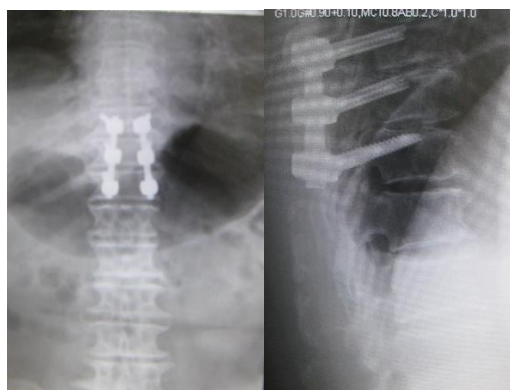
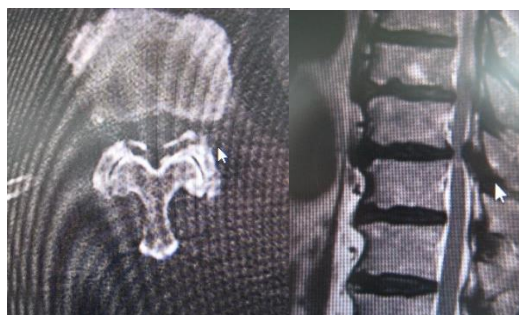This is my last time visiting memorial hospital during this stay. Dr. Fujiya was the surgeon of operation in the morning. I heard that Dr. Fujiya has

been famous for the fast surgery. I enjoyed the sprightly surgical rhythm very much and Dr. Fujiya finished a one level PLIF within 1.5 hours. I can't believe he is almost seventy and still active in surgery. After assisting Dr. Takeuchi's surgery in the afternoon, I had attended surgeries by all five spine doctors in memorial hospital during the short stay in Hokkaido. How lucky I am! I am really thankful for that staff in this hospital serve me so kindly.

13th Nov (Thu) National Hospital Organization Hokkaido Medical Center

I visited Dr. Manabu Ito in Hokkaido Medical Center on 13th Nov, the first day of snowing in Sapporo flat. This hospital had a long history and it acted as hospital responsible for TB patients. It was re-formed recently and Orthopedic Department had been newly established after Dr. Ito arriving this April. The most dominant department here is Neurology and it is a national hospital so there were lots of difficult cases and patients referred from other places. That was the reason why Dr. Ito had been here. The case today was also very complicated. She is a patient with OLF over T9-11 with paraplegia but the surgery was postponed due to fatal comorbidity of thromboembolism. After being controlled by cardiologist. She received surgery today. Dr. Ito is a perfect tutor. He loves teaching and has an excellent English pronunciation. He had been


already an international famous doctor, also in my country, Taiwan. He demonstrated the surgery, and explained the principles and pitfalls in CBT screw and OLF treatment, steps by steps. After the surgery, he took us for a ward round and enjoyed a substantial academic discussion.



Posterior decompression for OLF and instrumentated fusion with CBT by Professor Ito.



National Hospital Organization Hokkaido Medical Center, Sapporo



Me, Dr. Katsuhisa Yamada(2nd from left), Professor Manabu Ito(2nd from right) and Dr. Ashish Tomar

* Culture and Life

For me, this fellowship was not only a knowledge renew and refill, but also a memorial life experience. During 3 week stay in Sapporo city, I tried to keep pace with people here. Enjoying Japanese style food, taking subway in workday morning, watching a baseball game at the weekend and drinking in Susukino on Friday night. Sapporo, a city with combination of modern and nature, had been filled with my unforgettable memory.



Sapporo dome and city view in Hitsujiogaoka Hill



Night view in Moiwa



Sapporo Shitokeidai



Sapporo JR station




Sapporo TV tower in Odori Park



Snow makes university campus a silver world

My three week of stay in Hokkaido was satisfying. It my great honor to join the operation from Professor Abumi and spine surgeons from Hokkaido University Hospital and its affiliated hospitals, one of most famous and talented spine team around the world. As a visiting spine fellow, what I got was not only surgical knowledge and skills but also friendship between me, fellows from other countries and surgeons here. Especially I thank and respect Professor Abumi wholeheartedly for organizing this solid program.

Finally I will thank the APOA spine section especially the chairman, Professor Arvind Jayaswal and honorary secretary, Professor Mun-Keong Kwan for selecting me for clinical fellowship 2014. It will be a brilliant inspiration in my career. I also thanks for Dr. Chris Chan Yin Wei and Miss Cheryl for coordination this program.



Professor Abumi and me in the office

Operation assisted / observed during this fellowship

Date	Day	Age	Sex	Diagnosis	Procedure	Surgeon	My role	Hospital
27-Oct	Mon	82	F	L1 compression fracture status post BKP, failure	PI (T10-L3) with fusion in situ	Dr Y. Abe	Assistant	Eniwa Hospital, Eniwa
		65	M	L4/5 spondylolisthesis, grade I	TLIF L4/5	Dr Yanagibashi	Observer	Eniwa Hospital, Eniwa
28-Oct	Tue	78	F	L1/2 adjacent degeneration with stenosis	PI (L1-L3) with PLF	Prof K. Abumi	Assistant	Sapporo Orthopedic H, Sapporo
		60	M	L3/4 spondylolisthesis, grade I	PLIF L3/4	Prof K. Abumi	Assistant	Sapporo Orthopedic H, Sapporo
29-Oct	Wed	59	F	L4/5 spondylolisthesis, grade I	TLIF L4/5	Dr K. Suda	Observer	Hokkaido Central Spinal Cord Injury Center, Bibai
		14	M	C5/6 fracture dislocation, ASIA grade D	PI (C5/6 lateral mass screw)	Dr K. Suda	Assistant	Hokkaido Central Spinal Cord Injury Center, Bibai
		77	M	L2 compression fracture	Kyphoplasty	Dr K. Suda	Observer	Hokkaido Central Spinal Cord Injury Center, Bibai
		65	M	L4/5/S1 spondylolisthesis	TLIF L5/S1	Dr K. Suda	Assistant	Hokkaido Central Spinal Cord Injury Center, Bibai
30-Oct	Thu	79	F	Rheumatoid arthritis, C3/4/5 stenosis with myelopathy	PI (C2-T1) pedicle screw	Dr I. Oda	Assistant	Hokkaido Orthopedics Memorial Hospital, Sapporo
		63	M	Cervical stenosis, C3-6	Laminoplasty, Kurokawa	Dr I. Oda	Assistant	Hokkaido Orthopedics Memorial Hospital, Sapporo
31-Oct	Fri	54	M	Cervical myelopathy	Laminoplasty, Kurokawa	Dr I. Oda	Observer	Hokkaido Orthopedics Memorial Hospital, Sapporo
4-Nov	Tue	40	M	HIVD, C4/5 with myelopathy	ACDF (Cage)	Prof K. Abumi	Assistant	Sapporo Orthopedic H, Sapporo
		67	M	OPLL with cervical myelopathy	Laminoplasty, C2-6	Prof K. Abumi	Assistant	Sapporo Orthopedic H, Sapporo
		59	F	HIVD, L4/5, left	Open discectomy	Prof K. Abumi	Assistant	Sapporo Orthopedic H, Sapporo
5-Nov	Wed	69	M	L4/5 spondylolisthesis, grade I	TLIF L4/5	Dr K. Suda	Assistant	Hokkaido Central Spinal Cord Injury Center, Bibai
		53	F	HIVD, L5/S1, right	Microdiscectomy	Dr K. Suda	Observer	Hokkaido Central Spinal Cord Injury Center, Bibai

6- Nov	Thu	67	M	OPLL with cervical myelopathy	Laminoplasty, (C2-7) muscle preserving	Dr M. Takahata	Observer	Hokkaido University Hospital
		88	F	OLF, T7-9 ; Lumbar stenosis, L2-5	Laminectomy	Prof K. Abumi	Assistant	Sapporo Orthopedic H, Sapporo
7- Nov	Fri	40	M	HIVD, L4/5, left	Microdiscectomy	Dr Y.Murota	Assistant	Hokkaido Orthopedics Memorial Hospital, Sapporo
		60	M	Cervical myelopathy	Laminoplasty, Kurokawa	Dr Y.Murota	Assistant	Hokkaido Orthopedics Memorial Hospital, Sapporo
10- Nov	Mon	72	M	L3/4 spondylolisthesis, grade I with extraforaminal HIVD	PI (L3/4, CBT) + PLIF	Dr Y. Abe	Assistant	Eniwa Hospital, Eniwa
11- Nov	Tue	27	F	AIS, Lenke 2A-	PI (T2-L3)+osteotomy	Dr H. Sudo	Observer	Hokkaido University Hospital
		74	F	cervical kyphosis with stenosis	PI (C2-6, pedicle screws)+ PD foraminotomy	Prof K. Abumi	Assistant	Sapporo Orthopedic H, Sapporo
		77	M	Isthmic spondylolisthesis L5/S1, grade II	PLIF L5/S1, Hybrid (S1 CBT)	Prof K. Abumi	Assistant	Sapporo Orthopedic H, Sapporo
12- Nov	Wed	52	M	foraminal stenosis, L4/5	PLIF L4/5	Dr M. Fujiya	Assistant	Hokkaido Orthopedics Memorial Hospital, Sapporo
		82	M	L2-5 stenosis, spondylolisthesis, L4/5	PLF L4/5 ; PD L2-5	Dr H. Takeuchi	Assistant	Hokkaido Orthopedics Memorial Hospital, Sapporo
13- Nov	Thu	74	F	OLF, T9-11 ; Lumbar stenosis, L3/4	PD+PI(CBT)+PF T7-9 ; PD L3/4	Dr M. Ito	Assistant	National Hospital Organization Hokkaido Medical Center