

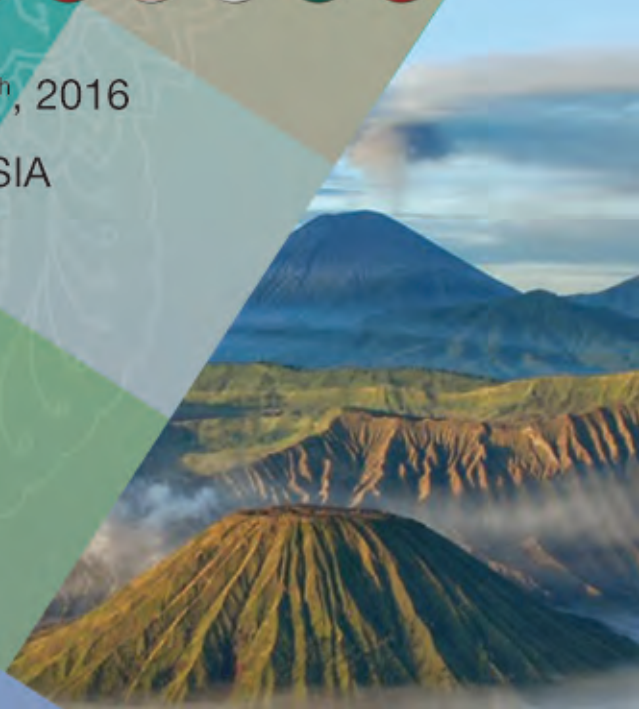

# APSS ASIA PACIFIC SPINE SOCIETY Surabaya Operative Course



December 16<sup>th</sup> – 18<sup>th</sup>, 2016

Surabaya, INDONESIA





**Central Sponsors**

**Medtronic**



**Contents**

Local Organizing Committee	2 – 3
Asia Pacific Spine Society Executive Committee	4
Message from the Director of Dr Soetomo General Hospital	5
Message from the President of the Asia Pacific Spine Society	6 – 7
Message from the Local Organizing Chairman	8
Faculty – International & Local	9 – 13
Proposed Cases	14
Daily Program	15 – 17
Abstracts	18 – 30
Acknowledgements	31



## Local Organizing Committee

*Protector* Soetomo General Hospital Director  
Head of Orthopaedic & Traumatology  
Department, Soetomo General Hospital  
Surabaya

*Chairman* I Ketut Martiana MD

*Vice Chairman* Tri Wahyu Martanto MD

*Secretary* Lukas Widhiyanto MD  
Imelda Lumban Gaol MD

*Treasurer* Teddy Heri Wardhana MD  
Dra Suparti

*Scientific & Workshop* Primadenny Ariesa Airlangga MD, MSi  
Achmad Fachrizal MD  
Stacy Brahmana MD  
OK Ilham A Irsyam MD  
Brilliant Citra Wirashada MD  
Citra Adhi Prasetya MD  
Kukuh Dwiputra Hernugrahanto MD  
Donny Permana MD  
Hudaya Nikmatullah MD  
Reyner Valiant Tumbelaka MD

*Publication & Documentation* Mouli Edward MD  
Hizbillah Yazid MD  
Dionysius Bramta Putra Manyakori MD  
Trixie Brevi Putri MD  
Pandu MD  
I Putu Pradana MD

*Accommodation & Transportation* Sulis Bayusentono MD  
Ritzky Pratomo Affan MD  
Ahmad Hannan Putra MD  
Taufan Mulyo Wibisono MD  
Arifin MD



## Local Organizing Committee

[continued]

*Equipments* M Hardian Basuki MD  
Andi Bahauddin Fahmi MD  
Rizky Agung Satria MD  
Kadek Seta Prawira MD  
Deny Mory Aryawan MD  
Henry Dominica MD

*Licensing* Yesa A Suwandani MD  
Agung Malinda Wijaya MD  
I Gusti Ngurah Dodo Mulyawan Ranuh MD

*Consumption* Ameria Pribadi MD  
Suyenci Limbong MD  
Tabita Prajasari MD

*Secretariat* Titiek Widarti

*Registration* Orthopaedic and Traumatology Secretariat  
– Dr Soetomo General Hospital Surabaya



**Asia Pacific Spine Society  
Executive Committee**



**Dr Kuniyoshi Abumi**  
JAPAN  
PRESIDENT



**Dato' Dr K S Sivananthan**  
MALAYSIA  
PRESIDENT ELECT



**Dr Kwan Mun Keong**  
MALAYSIA  
HONORARY SECRETARY



**Dr Wong Yat Wa**  
HONG KONG  
TREASURER



**Dr Arvind Jayaswal**  
INDIA  
COMMITTEE MEMBER



**Dr Jae Yoon Chung**  
KOREA  
COMMITTEE MEMBER



**Dr Hee Kit Wong**  
SINGAPORE  
COMMITTEE MEMBER



**Dr Keith Dip Kei Luk**  
HONG KONG  
COMMITTEE MEMBER



**Message from the Director of  
Dr Soetomo General Hospital**



*On behalf of Dr Soetomo General Hospital Directors, we are extending a warm welcome to all participants and speakers of the APSS Surabaya Operative Course which will be held on December 16 – 18, 2016. It is very big pleasure for us to host the APSS Operative Course in Surabaya at our facility.*

*Our hospital is known as the top referral hospital in eastern part is Indonesia. The large number of patients with so many complex cases are being treated in our facilities. As our effort to develop the quality of care to patients, we have objectives which stated in our vision and missions to provide safe, effective and efficient care equally to all patients. We are always encouraged to provide the best care practices which often need advanced methods and skills.*

*Medical technology which is rapidly need in this era has challenged us as medical practitioners as well as intellectuals to adapt for those fast changing and high technology needs. No exception for orthopaedic field, specifically on spine surgery which is known for its advancement on methods and machines. By knowing this fact, it surely is essential to develop the individual quality itself. The value that has been promised by this event is clearly beneficial for the enhancement of skill and knowledge on spine surgery field.*

*The global collaboration with international professional organization has opened the gate of information and medical technology enhancement. As our spine surgeons have been maintaining communication with Asia Pacific Spine Society (APSS) through this operative course event, we believe that it will greatly contribute to the development and enhancement of spine surgery methods & techniques to all the participants and more widely to all developing hospital throughout Indonesia.*

*Lastly, we wish that all the participants will have a great opportunity to learn and achieve maximum benefits & values from this APSS Operative Course.*

*Best regards,*

*Harsono, MD*

*Director of Dr Soetomo General Hospital*



## Message from the President of the Asia Pacific Spine Society



*Dear Colleagues,*

*It gives me the greatest pleasure to welcome you to join us at the Surabaya Operative Spine Course of the Asia Pacific Spine Society (APSS) which is held in Dr Soetomo General Hospital, Surabaya, City, East Java, Indonesia from December 16 – 18, 2016. Following the previous successful operative course held in Bandung, the APSS is very excited to be back again in Indonesia for another operative course that comprises a larger group of international and local faculty members which are of*

*high quality. Similar operative spine courses have been held once or twice annually in many Asian countries including Bangladesh, Cambodia, China, India, Japan, Korea, Malaysia, Myanmar, Nepal, Philippines, Sri Lanka, Taiwan, Thailand and Vietnam.*

*The course will provide a wonderful forum for you to enhance the principal and advanced knowledge of pathological conditions of spinal disorders and explore the latest surgical techniques of spinal surgery. As a regional based society, we are striving to offer plenty of networking opportunities, providing you with the opportunity to meet and interact with the leading Asian spine specialists and researchers in the field of spine surgery, friends and colleagues as well as exhibitors through lectures and saw bone workshops during the course. The highlight of the course is the showcase of live surgeries conducted by both our faculty members and local team, in which the surgeries will be transmitted live to the auditorium to facilitate the learning of the surgical techniques. Simultaneously, the delegates are able to discuss with the surgeons during and after their operations regarding various interesting surgical issues such as how to improve the good results of the surgeries and how to avoid complications.*

*On behalf of the APSS, I would like to express my deepest appreciation to the society's partners of this course, i.e. Medtronic and DePuy Synthes, for their unwavering support to our educational activities, and to the local organizing chairman, Dr Ketut Martiana and his team whose leadership and conscientious efforts have contributed to such a successful partnership.*

*Alongside the educational program, Surabaya and its environs are an amazing place to visit. The city is known as Kota Pahlawan "city of heroes" due to the importance of the Battle of Surabaya in galvanizing Indonesian and international support for Indonesian independence during the Indonesian National Revolution. Short distances away are wonderful attractions such as Jalesveva Jayamahe Monument and Hero Monument. The city also has easy access to the Mount Bromo for those who are interested in visiting the active volcano that promises spectacular views and*



## Message from the President of the Asia Pacific Spine Society

[continued]

*dramatic landscapes. The course promises to be highly rewarding on an intellectual basis as well as on a social basis.*

*We look forward to your active participation in joining us for a symphony of outstanding science, and take a little extra time to enjoy the breathtaking natural beauty of this region.*

*With warmest regards,*

**Kuniyoshi Abumi, MD**

*President of the Asia Pacific Spine Society*



## Message from the Local Organizing Chairman



*Dear Participants,*

*On behalf of The Executive Committee of APSS, the Indonesian Orthopaedic Association and the local organizing Committee, we would like to invite you to attend the APSS Surabaya Operative Course in Dr Soetomo Hospital, Surabaya in 16<sup>th</sup> – 18<sup>th</sup> December 2016. We are delighted to welcome you to this event. This event is a part of APSS educational activities and we prepare specially for you a workshop and lectures from outstanding experts around Asia Pacific to share*

*their current knowledge and experience. We also prepare case discussion and live surgery in Dr Soetomo General Hospital, and we would give golden chances for participants to directly assist the live surgeries with those experts.*

*Beside the scientific meeting, I would like to encourage you to leisurely visit the Mt Bromo, which is one of still active mountains in Indonesia with great scenery. A gala dinner will also be held on Saturday for you to socialize and network with your colleagues and the experts. So, please join us.*

*On behalf of APSS chairman and local organizing committee, I kindly invite you to follow this event and enjoy it as a nice discussion with very distinguish experts. Please enjoy Surabaya.*

*Warm regards,*

**Ketut Martiana, MD**

*Local Organizing Chairman*



## Faculty – International & Local



**KUNIYOSHI ABUMI**  
*Center for Spinal Disorders,  
Sapporo Orthopaedic Hospital  
Hokkaido University  
JAPAN*



**DATO' K S SIVANANTHAN**  
*Orthopaedics & Traumatology Department,  
Hospital Fatimah, Ipoh  
MALAYSIA*



**ARVIND JAYASWAL**  
*Department of Spine Surgery,  
Primus Super Speciality Hospital  
New Delhi  
INDIA*



**JAE YOON CHUNG**  
*Department of Orthopaedics,  
Chonnam University Hospital  
KOREA*



### Faculty – International & Local

[continued]



**KEITH DIP KEI LUK**  
*Department of Orthopedics & Traumatology,  
The University of Hong Kong*  
HONG KONG



**MUN KEONG KWAN**  
*Spine Unit, University of Malaya, Kuala Lumpur  
University Malaya Medical Centre, Kuala Lumpur*  
MALAYSIA



**YAT WA WONG**  
*Department of Orthopedics & Traumatology,  
The University of Hong Kong  
Queen Mary Hospital*  
HONG KONG



**GABRIEL LIU**  
*Department of Orthopaedic Surgery,  
National University of Singapore  
National University Health System (NUHS)*  
SINGAPORE

### Faculty – International & Local

[continued]



**JOSE MANUEL F IGNACIO**  
*Department of Orthopedics,  
University of the Philippines  
Philippine General Hospital*  
PHILIPPINES



**SHU-HUA YANG**  
*Department of Orthopedics,  
National Taiwan University Hospital*  
TAIWAN



**MD SHAH ALAM**  
*Department of Spine & Orthopaedic Surgery,  
National Institute of Traumatology &  
Orthopaedic Rehabilitation (NITOR)*  
BANGLADESH



**KYU JUNG CHO**  
*Department of Orthopedic Surgery,  
Inha University Hospital, Incheon*  
KOREA



### Faculty – International & Local

[continued]



**WEN-TIEN WU**  
*Department of Orthopedics,  
Hualien Tzu Chi Hospital  
Buddhist Tzu Chi Medical Foundation  
Tzu Chi University  
TAIWAN*



**CHRIS YIN WEI CHAN**  
*Spine Unit, University of Malaya, Kuala Lumpur  
University Malaya Medical Centre, Kuala Lumpur  
MALAYSIA*



**BAMBANG TIKSNADI**  
*Department of Orthopaedic and Traumatology,  
Dr Hasan Sadikin Hospital, Bandung  
INDONESIA*



**LUTHFI GATAM**  
*Orthopaedic and Traumatology Department,  
School of Medicine University of Indonesia,  
Jakarta  
Fatmawati General Hospital, Jakarta  
INDONESIA*

### Faculty – International & Local

[continued]



**DOHAR TOBING**  
*Department Medik Orthopaedic &  
Traumatology RSCM, Jakarta  
INDONESIA*



**KETUT MARTIANA**  
*Orthopaedic Department,  
School of Medicine Airlangga University, Surabaya  
Dr Soetomo General Hospital, Surabaya  
INDONESIA*



**HARDIONO**  
*Anesthesiology and Reanimation Department,  
School of Medicine University of Airlangga, Surabaya  
Premier Hospital, Surabaya  
INDONESIA*





## Proposed Cases

1. **Cervical Spine**
  - a. Anterior Cervical i.e. ACDF or ACCF
  - b. Anterior Cervical i.e. Arthroplasty
  - c. Posterior Cervical Fixation i.e. Lateral Mass or Pedicle Screw Fusion
  - d. Posterior Cervical Decompression i.e. Laminoplasty
  - e. Posterior Cervical C1/2 Fusion
  - f. Posterior Occipitocervical Fusion
2. **Coronal Deformity Correction**
  - a. Adolescent Idiopathic Scoliosis i.e. Posterior Instrumented Spinal Fusion
3. **Sagittal Deformity Correction**
  - a. Ankylosing spondylitis
  - b. Scheuermann kyphosis
  - c. Neglected traumatic fracture
  - d. TB spine kyphosis
4. **Spinal Instability +/- Neurological Deficit for Stabilization +/- Decompression**
  - a. Traumatic acute fracture
  - b. Spinal infection
  - c. Spinal metastases
5. **Lumbar Spinal Stenosis (LSS)**
  - a. Decompression alone i.e medial facetectomy, laminectomy or internal laminolasty, discectomy for HNP
  - b. Decompression and fusion i.e. Open TLIF, MIS TLIF or DLIF

## Daily Program

### DAY 1 – 16<sup>TH</sup> DECEMBER 2016, FRIDAY

0900 – 1200	Pre-Operative Cases Discussion
1300 – 1400	Registration of Participants
1400 – 1530	<b>Saw Bones Workshop 1</b> Thoracic Pedicle Screw, Lumbar Pedicle Screw, S1 Screw, Iliac Screw and S2AI Screw Fixation <i>Gabriel Liu, Shu-Hua Yang</i>
1530 – 1700	<b>Saw Bones Workshop 2</b> Posterior Instrumentation of Cervical Spine i.e. C1/C2 Fixation, Lateral Mass and Cervical Pedicle Screw Fixation / Anterior Cervical Discectomy Fusion <i>Kuniyoshi Abumi, K S Sivananthan</i>

*\*The final operative list/ cases will be decided on 16<sup>th</sup> December 2016 during the pre-operative assessment. 10 – 14 cases will be selected from the above list for live surgery telecast during the entire 3-day course.*



### Daily Program

#### DAY 2 – 17<sup>TH</sup> DECEMBER 2016, SATURDAY

0700 – 0800	Registration of Participants
0800 – 0820	<b>OPENING CONFERENCE</b> – Hospital Director's Welcome Speech <i>Harsono</i> – The Organising Chairman's Welcome Speech <i>Ketut Martiana</i> – The APSS President's Welcome Speech <i>Kuniyoshi Abumi</i>
0820 – 0835	Ethics in Spine Surgery <i>Ketut Martiana</i>
0835 – 0850	Patient Safety Matters in Spine Surgery <i>Hardiono</i>
0850 – 0905	Pathophysiology of Disc Degeneration and the Production of Pain [page 19] <i>Jose Manuel F Ignacio</i>
0905 – 0920	Surgical Management of Cervical OPLL: Anterior or Posterior Approach? [page 20] <i>Kuniyoshi Abumi</i>
0920 – 0935	TLIF with Cortical Pedicular Screw Fixation [page 21] <i>K S Sivananthan</i>
0935 – 0950	Less Invasive Expansive Open Door Laminoplasty for Multiple Level Cervical Spondylotic Myelopathy [page 22] <i>Wen-Tien Wu</i>
0950 – 1005	How to Choose between Fusion and Artificial Disc Replacement for Lumbar Degenerative Disc Diseases? [page 23] <i>Bambang Tiksnadi</i>
0800 – 1700	<b>LIVE SURGERY</b> (Kindly refer to the OT list attachment which will be distributed) – Operation Theatre 1: – Operation Theatre 2: – Operation Theatre 3:
1900 – 2100	<b>GALA DINNER</b> Venue: Ballroom Ciputra Golf Palimanan Restaurant, 2nd Floor, Ciputra Golf, Club & Hotel, Jl. Citra Raya Utama



### Daily Program

#### DAY 3 – 18<sup>TH</sup> DECEMBER 2016, SUNDAY

0800 – 0815	Discussion and Evaluation: Post-Op Cases Done on DAY 2
0815 – 0830	Thoracic and Lumbar Pedicle Screw Fixation [page 24] <i>Kyu Jung Cho</i>
0830 – 0845	Surgical Management of Kyphotic Deformity in Ankylosing Spondylitis [page 25] <i>Keith Dip Kei Luk</i>
0845 – 0900	Selecting Fusion Levels in AIS Surgery [page 26] <i>Gabriel Liu</i>
0900 – 0915	Congenital Scoliosis: Management Principles [page 27] <i>Yat Wa Wong</i>
0915 – 0930	Severe Scoliosis: Treatment Options [page 28] <i>Arvind Jayaswal</i>
0930 – 0945	Minimally Invasive Spine Surgery in Spinal Metastasis [page 29] <i>Chris Yin Wei Chan</i>
0945 – 1000	Degenerative Spondylolisthesis [page 30] <i>Luthfi Gatam</i>
0800 – 1700	<b>LIVE SURGERY</b> (Kindly refer to the OT list attachment which will be distributed) – Operation Theatre 1 – Operation Theatre 2 – Operation Theatre 3
1700	Closing and Certificate Presentation



# ABSTRACTS

## **PATHOPHYSIOLOGY OF DISC DEGENERATION AND THE PRODUCTION OF PAIN**

**Jose Manuel F Ignacio**

*Department of Orthopedics, University of the Philippines,  
Philippine General Hospital, Philippines*

Despite all the literature printed on Degenerative Disc Conditions, there is still no universally accepted definition. The biochemist will define it different from an anatomist which will be different from that of pathologists viewpoint which differs from the way a clinician will approach the condition and so will a radiologist, and so on and so forth.

From the initial dissertation of Kirkaldy Willis on the degenerative cascade on spinal degeneration, there have been newer studies to refine and augment our understanding of the degenerative process. Genetic influences as well as more detailed understanding of the biochemical processes affecting the degenerative process of the spinal column are now becoming established knowledge. These shall be discussed in the presentation



### SURGICAL MANAGEMENT OF CERVICAL OPLL: ANTERIOR OR POSTERIOR APPROACH?

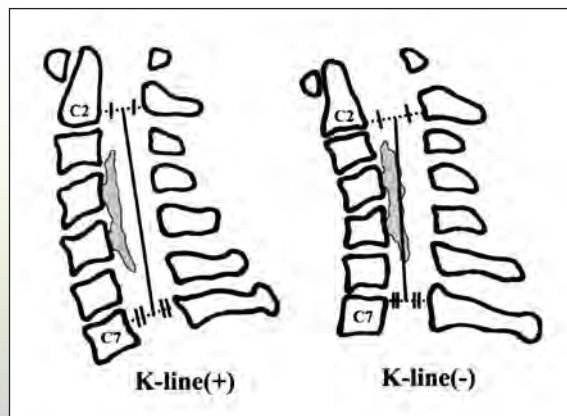
**Kuniyoshi Abumi**

*Sapporo Orthopaedic Hospital-Center for Spinal Disorders*

Patients with myelopathy caused by ossification of the posterior longitudinal ligament (OPLL) require surgical intervention. Direct anterior decompression by floating or excision of OPLL is effective for ventrally compressed cervical spinal cord by OPLL. Decompression through posterior approach is also effective for major cases of OPLL in the cervical spine with physiological lordosis. Posterior procedure include several types of laminoplasty have been developed for cervical OPLL. There are controversy for selection of surgical procedure among the spine surgeons.

Suda and Abumi showed that kyphotic alignment of the cervical spine is major factor causing poor surgical outcome after laminoplasty for cervical spondylotic myelopathy. Fujiyoshi et al proposed the K-line defining as a line that connects the midpoints of the spinal canal at C2 and C7 (Fig). They demonstrate that a sufficient posterior shift of the spinal cord and neurologic improvement will not be obtained after posterior decompression surgery in the K-line (-) group. Matsumoto et al showed that preoperative kyphosis of the cervical spine and severe (>60%) compromise of the spinal canal by OPLL appear to be the limiting factors for the indication of laminoplasty. Yoshii et al demonstrated that the postoperative recovery rate was similar in the posteriorly and anteriorly managed groups, and in patients with massive OPLL with kyphotic alignment, neurologic recovery rate in the anterior was superior to that in the posterior. However, they resulted that the occurrence of perioperative complications was more common in the anterior group.

Surgical procedure for cervical OPLL must be selected considering cervical alignment in the sagittal plane, canal occupying ratio by ossified ligament, types of ossification, etc.



### TLIF WITH CORTICAL PEDICULAR SCREW FIXATION

**K S Sivananthan**

*Hospital Fatimah, Ipoh, Perak, Malaysia*

Midline lumbar fusion (MIDLF) using cortical pedicular screws is a new alternative for minimally invasive surgery.

This technique has the following benefits :-

1. Small incision (4-5 cm) (same as the laminectomy incision)
2. No extension needed for screw insertion
3. Less muscle damage
4. Almost 0 muscle retraction
5. Less blood loss
6. Higher pull out strength and equivalent construct strength vs traditional PS fixation

The cortical screw fixation is from the inframedial aspect of the pedicle to the supralateral aspect of the pedicle. The cortical screw which is usually 4.5 - 5 mm is inserted obliquely.

This fixation for spinal fusion has the following advantages :-

#### Fixation

- Trajectory maximizes cortical bone contact

#### Visualization

- Single small midline incision
- Familiar open anatomy with clear visualization
- Not restricted by a tubular retractor

#### Preservation

- Less muscle disruption than traditional open technique
- Less neurovascular elements compromised
- Capsules of posterior joints not damaged
- Less blood loss



## LESS INVASIVE EXPANSIVE OPEN DOOR LAMINOPLASTY FOR MULTIPLE LEVEL CERVICAL SPONDYLOTIC MYELOPATHY

Wen-Tien Wu

*Department of Orthopedics, Hualien Tzu Chi Hospital,  
Buddhist Tzu Chi Medical Foundation, Tzu Chi University, TAIWAN*

Expansive open-door laminoplasty (EOLP) is a safe and effective surgical method for treating multilevel cervical spondylotic myelopathy (MCSM). The approach, developed by Hirabayashi in 1977, involves fixing the opened laminae by using suture material. This method was found to yield a high incidence of lamina reclosure. O'Brien et al. in 1996 reported a method of applying maxillofacial miniplates and screws to provide primary resistance against lamina reclosure. Between 2005 and 2011, we conducted EOLP securing by using titanium miniplates and screws for treating MCSM and observed favorable surgical results. However, several predominant complications of this method were still noted; approximately 42% of the treated patients exhibited moderate to severe postoperative axial neck pain, 35% experienced a loss of range of motion (ROM), and 2.8% displayed C5 nerve palsy.

To reduce the incidence rates of these complications, we developed a modified EOLP (MEOLP) method, which we have used since 2011 and evaluated in a retrospective study. By reducing surgical dissection by preserving the unilateral paraspinal musculature, preserving the C7 spinous process, and creating more medial gutter for reducing facet joint violation, the frequency of persistent postoperative axial neck pain and ROM loss significantly decreased with similar neurological outcomes at postop 1 year follow-up. Clinical and radiographic outcomes revealed significant recovery exhibited gradual improvement during 1–4 years after surgery. MEOLP also yielded satisfactory mid-term outcomes at postop 4 years follow-up. The mean JOA recovery rate of postoperative 4 years follow-up was 82.3% and 85% range of motion was observed. None of these patients experienced aggravated or severe neck pain or showed complications of temporary C5 nerve palsy and lamina reclosure.

Through combination of MEOLP with short segment fixation or long instrumented fusion, the advantages of laminoplasty can be more widely applied on the patients who suffered from MCSM.



## HOW TO CHOOSE BETWEEN FUSION AND ARTIFICIAL DISC REPLACEMENT FOR LUMBAR DEGENERATIVE DISC DISEASES?

Bambang Tiksnadi

*Department of Orthopaedic and Traumatology,  
Dr Hasan Sadikin Hospital, Bandung, Indonesia*

The Lumbar fusion for axial pain is an option for treatment of symptomatic degenerative diseases refractory to non surgical treatment. Results following fusion surgery may be unsatisfactory due to persistent pain despite achievement of a radiographically healed fusion. The Artificial Disc Replacement (ADR) as an alternative of surgical procedure base on to diminish complications after fusion procedure done. But after several years of experiences there are still lots of complications happen. One of the causes is improper surgical indication, because up to now there is no classification system has taken into account the state of degeneration of facet joint which was believed have an important role on selecting proper surgical procedures for DDD.

The classification system of Lumbar DDD is important for comparison of data from different investigators using same terminology. The precise and accuracy of the degree of degeneration is paramount to the clinical success of the chosen treatment.

Prior Classification of DDD, are based on MRI signal intensity alone, while the internal disruption of the disc is not reliably diagnosed by MRI alone, must be include provocative discography and plain radiographs.

The success of an ADR (Artificial Disc Replacement) depends on the state of facet joint degeneration.

Simple classification based on evaluation of MRI, plain x-ray, provocative discography is mandatory to explain the condition of anterior and posterior column of intervertebral segment is necessary.



## THORACIC AND LUMBAR PEDICLE SCREW FIXATION

**Kyu-Jung Cho**

*Department of Orthopedic Surgery, Inha University Hospital, Jung-Gu,  
Incheon, Korea*

Pedicle screw fixation is widely used as lumbar and thoracic spine instrumentation. Pedicle screws must be inserted in the correct position to prevent complications such as nerve root or vascular injury. Entry point for screw placement is different according to the level of the spine. In the thoracolumbar spine (T10-L5) it starts at the intersection between midpoint of transverse process and lateral margin of the facet joint. In the mid thoracic spine, it starts at the intersection between the upper margin of the transverse process and just medial to lateral margin of the articular process.

In a normal spine, the screws proceed with a convergent angle of 15-20 degrees in the upper thoracic and lumbar spine. In the thoracolumbar spine the screws should be inserted more vertically. In a deformed spine the direction of the screw is different according to the deformity. On the concave side the screws proceed vertically, while on the convex side they should be go forward more convergently depending on how much the vertebral rotation is.

In an osteoporotic spine, a few drills are helpful to enhance screw purchase. First, avoid too much strain on screws. Surgeons exert compression or distraction force on the screws, which may cause screw loosening and loss of correction. Second, be aware of how to insert screws firmly. Inserting screws convergently provides more purchase power than inserting vertically. Sacral screws are likely to be loosened. Three point fixation technique aiming at the superior endplate of the sacrum assures the highest pull out strength in the sacral fixation. Third, cement augmentation on the screws is the most powerful technique. Cement is injected into the vertebral body using a cannula, and then insert screws. There are also specially designed screws that have holes on the screw shaft through which the cement leaks out.



## SURGICAL MANAGEMENT OF KYPHOTIC DEFORMITY IN ANKYLOSING SPONDYLITIS

**Keith D K LUK**

*Department of Orthopedics & Traumatology, The University of Hong Kong,  
Hong Kong*

Ankylosing spondylitis typically affects the large girdle joints and the axial skeleton with bony ankyloses of the synovial joints resulting in stiffness and deformity. The commonest deformity is kyphosis affecting the thoracolumbosacral spine and less so at the cervical spine leading to sagittal balance and a low gaze angle. Stress fractures with or without dislocations can occur with minor injuries frequently complicated by nonunion and pseudoarthrosis formation. Fortunately with more effective medical treatment in the recent decades the incidence of severe deformity is obviously on the decline.

There is still controversy on whether one should tackle the hips or spinal deformity first but most surgeons are in favor of the former which is a relatively simpler surgery with more reliable outcome. Spinal extension osteotomy with shortening of the posterior column is preferred to anterior column lengthening. Correction at the maximum kyphosis should give the best cosmetic effect. However an osteotomy at the lower lumbar segment can magnify the amount of sagittal translation and is safer neurologically. Multilevel Ponte type of osteotomy can produce a smoother contour of correction but each osteotomy can only provide <10 degrees of correction. A single level pedicular subtraction osteotomy with resection of the middle column can typically provide 30 degrees of extension correction. Vertebral column resection is seldom needed in AS. The location and number of the osteotomies depend on the morphology and severity of the deformity. A careful preoperative planning with simple xray templating or software programs should be done. One should be aware of the location of the 'new apex' of the kyphosis after correction and thus avoid ending the instrumentation at this site. Stress fractures at the junction can occur if not handled appropriately.

Positioning of the patient intraoperatively can be a challenge to the anesthesiologist. Supporting frames may have to be tailor made for deformities of different severities. Electrophysiologic monitoring is mandatory especially when osteotomies are performed at the cord level. Successful correction of kyphotic deformity in ankylosing spondylitis is very rewarding not only physically but also on the self-esteem of the patient.



## SELECTING FUSION LEVELS IN AIS SURGERY

**Gabriel Liu**

*Department of Orthopaedic Surgery, National University of Singapore,  
National University Health System (NUHS), SINGAPORE*

Adolescent Idiopathic Scoliosis is a common spinal deformity. If the condition progresses, it can result in significant morbidity and even mortality. The aim of this talk is to describe the surgical management of the Adolescent Idiopathic Scoliosis. We shall discuss common terminologies, surgical fusions level selection and outcomes.



## CONGENITAL SCOLIOSIS: MANAGEMENT PRINCIPLES

**Yat Wa Wong**

*Department of Orthopedics & Traumatology,  
The University of Hong Kong, Queen Mary Hospital, Hong Kong*

The prevalence rate of congenital scoliosis is on average about 1 in 1000 live births. The exact cause for most cases are unknown. Since the cardiovascular system, genitourinary tract and spine develop at the same embryologic period, anomalies at these organ systems may appear at same patients. Congenital scoliosis can be classified according to the pathogenesis at the embryonic stage:

1. Failure of formation.
2. Failure of segmentation.
3. Mixed anomaly.
4. Hemimetameric shift.
5. Complex anomaly.

The natural history of the congenital scoliosis is affected by the types of vertebral anomalies, location, age and the associated rib fusion. Among all the factors, the types of anomalies are the most important factor to predict the final outcome of the deformity. McMaster's publication provides reliable prediction of the natural history.

Most patients are asymptomatic apart from the deformity. However, subtle evidence of minor neurological deficit, such as feet deformity, limb muscle atrophy or asymmetric reflexes, may suggest spinal dysraphism. Treatment options depend on the natural history. Bracing is usually ineffective for the primary curves but may be helpful to control the compensatory curves. For patients with more severe scoliosis or likely develop severe deformity before skeletal maturity, surgery is indicated. Before any surgical correction, MRI whole spine is mandatory to exclude any spinal dysraphism.

Surgeons should intervene before the deformity becomes severe and rigid. However, for established severe cases, preoperative halo traction is a safe way to get a better correction. A variety of operative strategies are available. They include in situ fusion, convex hemiepiphysiodesis +/- concave distraction, hemivertebra excision, growing rods, VEPTR or vertebral column resection. Many factors may affect the choice of surgery. They include type of deformity, severity, age, expertise, risk parents can accept and social economic support.



### SEVERE SCOLIOSIS: TREATMENT OPTIONS

**Arvind Jayaswal**

*Department of Spine Surgery, Primus Super Speciality Hospital,  
New Delhi, India*

The result of scoliosis correction is influenced by many factors, such as the severity of deformity, spine flexibility, apical rotation, patient's age, type of deformity, and associated abnormalities. Severe rigid scoliosis is more difficult to treat because the spine deformity is usually stiff – amenable only to radical release or osteotomy of the spine. The management of severe curves can potentially carry significant risk, especially with respect to blood loss, neurologic deficit and pulmonary compromise. However, the benefit of this surgical treatment is potentially far reaching from a cosmetic, pulmonary, and general health viewpoint which may prolong many of these patient's lives and give tremendous confidence & psychological boost to their personality.

In developing countries, a large chunk of scoliosis patients present late. There is still no consensus in the management of these rigid curves. Combined anterior and posterior radical release with instrumentation is generally required for correction of these deformities. However, there has been a shift to posterior only approach with multiple osteotomies and vertebral column resections for correction of all rigid deformities with the advent of segmental pedicle screw-rod instrumentation. The role of anterior release today has become questionable with good results from posterior approach alone.

We evaluated the outcome of Staged anterior release and posterior instrumentation for rigid scoliosis with curve more than 90° & share our experience of treating these challenging deformities

In our experience, a Staged approach to the management of severe, rigid scoliosis helps get a better correction. Anterior release loosens up the rigid apex so that the extent of the osteotomies in the second stage from the back is substantially reduced to get a good correction.



### MINIMALLY INVASIVE SPINE SURGERY IN SPINAL METASTASIS

**Chris Yin Wei Chan**

*Spine Unit, University of Malaya, Kuala Lumpur  
University Malaya Medical Centre, Kuala Lumpur, Malaysia*

With better diagnostic instruments and advancement in systemic therapy for oncological diseases, the prevalence of patients who present with spinal metastasis is on the rise. In this lecture, we would introduce the current concepts in the management of patients with spinal metastasis. Specifically, we will discuss surgical indications in spinal metastasis and how we incorporate treatment algorithms such as the Mayo algorithm and the Memorial Sloan Kettering algorithm (NOMS algorithm) as well as prognostic scoring system like the Tomita and Tokuehashi scores into our surgical decision making. With introduction of Long Construct Minimally Invasive Stabilization Techniques (MISt), we would also share our experience on the safety of percutaneous pedicle screw instrumentation in our population, the technical tips, tricks and how to avoid complications associated with instrumentation and discuss our clinical experience on the benefits of minimally invasive spine surgery compared to open spine surgery in spinal metastasis patients in a propensity matched study.





## DEGENERATIVE SPONDYLOLISTHESIS

**Luthfi Gatam**

*Spine Division Orthopaedic and Traumatology Department,  
Fatmawati Hospital Jakarta, Indonesia*

Spondylolisthesis is a condition characterized by anterior migration of cranial vertebrae in respect to the caudal vertebrae. The most common type of spondylolisthesis is degenerative spondylolisthesis. The incidence of spondylolisthesis is higher in woman over the age of 40 years old, and most commonly occurs in level L4-L5. The risk factor for degenerative spondylolisthesis are sacralization of L5 and sagittally oriented facet joints. The symptoms of spondylolisthesis include back pain and neurological symptoms. Dynamic radiograph and MRI are essentials in diagnosing and planning for the treatment of spondylolisthesis. Managements of spondylolisthesis include physical therapy, NSAID, epidural steroid injection, and surgery. Surgical treatment for degenerative spondylolisthesis may consist of decompression with or without instrumented fusion. Complications of spondylolisthesis are pseudoarthrosis, adjacent segment disease, surgical site infection, dural tear, and positioning neuropathy. Complication rates will increase with older age, increase blood lost, longer operative time, number of level fusion.



## Acknowledgements

*On behalf of the APSS, Local Committee of APSS Surabaya Operative Course and Department of Orthopedic & Traumatology, it has been a great honor to cooperate with your reputable and esteemed company.*

*We have been sharing the success of the course owing to your contribution and support. We hope that this relationship can be continued in the forthcoming years. We are looking forward to work with you in the future.*

# Medtronic

 **DePuy Synthes**  
COMPANIES OF *Johnson & Johnson*

  
PATRIOT MEDIKA NUSANTARA

  
PT DARMAWANGJA  
MEDICAL SUPPLIES

  
**ENDO**  
INDONESIA

**B | BRAUN**  
SHARING EXPERTISE

  
trafas

 **KALBE**

 **PT. KARUNIA ABADI INDONESIA**  
Hospital & Medical Supplier

**TRITON**<sup>TM</sup>  
manufactures

# Thanks

to our sponsors

Notes

---



---



---



---



---



---



---



---



---



---



---



---



---



---



---



---



---



---



---



---



---



