

Report for Asia Pacific Spine Society Depuy Synthes Traveling Fellowship 2015

Fellows:

Kyaw Min (Myanmar)
Ankur Patel (India)
Jun Ik Choi (Korea)
Waqar Alam (Pakistan)

Travel dates : May 18th to June 6th 2015

Purpose :

1. Travel to three spine centres to learn about the techniques for managing the different variety of spinal disorders
2. To attend the international conferences hosted by respective centres
3. To exchange knowledge among spine surgeons

It is actually a true honor to be selected for this traveling fellowship, which provides the unique lifetime experience to the participants. We were selected from different Asian Pacific countries (Myanmar, Korea, Pakistan and India) to travel around the Asia Pacific region.

First Centre: China

Date: 5/18/15 to 5/24/15

Venue: Peking Union Medical College Hospital, Beijing

Host: Guixing Qiu, MD

Beijing city gave a welcome to the APSS travelling fellows with the amazing surgical and scientific program. We had a chance to visit the Peking Union Medical College Hospital. It is 2000 bedded hospital with ten spine surgeons operated in four operating rooms from Monday to Friday. This hospital is famous for spinal deformity correction. With a national reputation of deformity correction surgeons, approximately 70 % of spinal deformity in China is undertaken in this hospital. Prof Guixing Qiu, Prof Zhaung and Prof Hu showed us various surgeries such as spinal deformity correction, hemivertebra resection, pedicle subtraction osteotomy, ACDF for cervical spondylosis and revision surgery with rod connectors with different techniques.



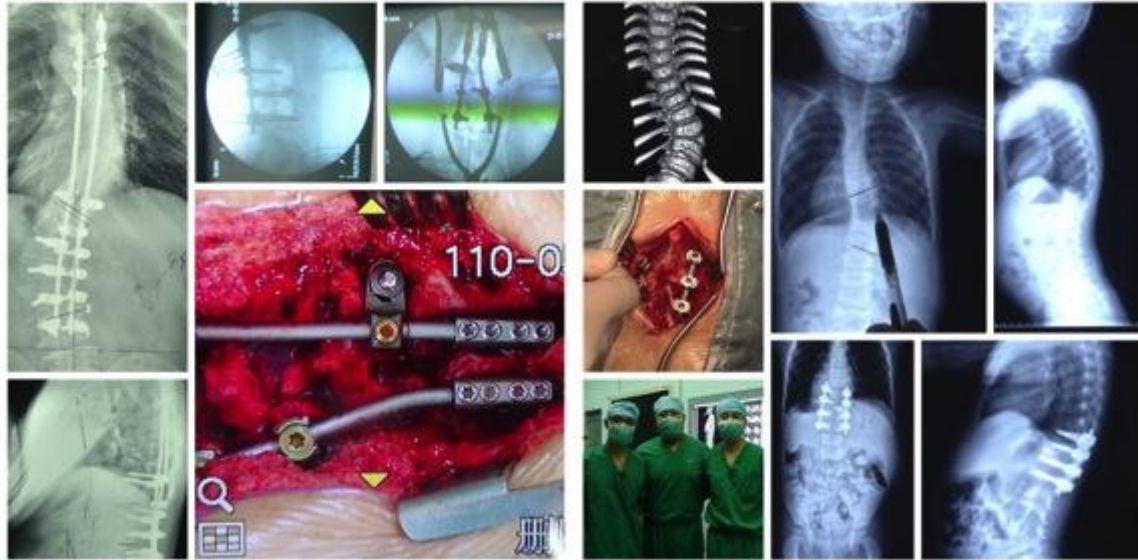
Peking Union Medical College Hospital

On 18 May, we observed Prof Qiu, head of the department, performed two cases, one case with lumbar spinal stenosis treated by posterior decompression and instrumentation from L2 to S1. Another case was congenital thoracic scoliosis due to hemivertebra treated by hemivertebra resection and pedicle screws fixation. The cell saver machine was routinely used in this hospital so that they can effectively reduce risk of blood transfusion. Prof Qiu introduced us with other spine surgeons operating in another rooms and explained about the location of operation room and facilities in order to orientate the operation theatre.

Every day there was a morning meeting at 7:00 am where all scheduled surgeries on that day were presented, and all previous day's operations were reported. Some interesting cases or tough cases would also be discussed. Ward round activity began after morning meeting, where we solved the complained and reviewed and discussed X rays of the all cases. After that, operation often started around 8:00am.

On 19th May, after morning conference, we followed Prof Zhaung, Consultant Orthopaedic Surgeon from Peking Union Medical College Hospital, for doing ward rounding. There were three cases lined up for operation. The first case was 13 year old girl with major thoracic scoliosis (cobb's angle 50') which was corrected by posterior instrumentation and fusion with intertransverse technique augmented by local made bone substitute. Prof Zhaung emphasized on prevention of adjacent segment disease by preserving proximal and distal ends of spinous process in instrumented fusion techniques. The second case was degenerated multilevel lumbar spinal stenosis treated by posterior decompression and fixation with pedicles screws and rods. In this case L4-5 disc was degenerated so the fusion level extended to S1. The last case was revision surgery for scoliosis patient who underwent operation last ten year back with pedicle screws and rods. Recently the patient was presenting with distal screws and left rod broken. The distal broken rod

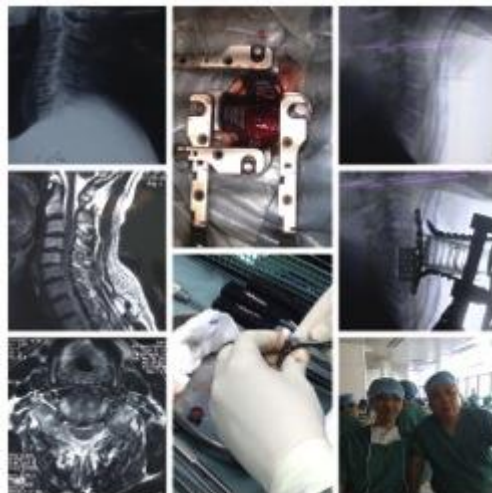was replaced by new one and connected with the proximal rod by using rod connector. The broken pedicle screws were replaced with larger one. Rod to rod connector is very useful in revision surgery because it not only makes operation easier but also shorten the operation time.



Revision scoliosis surgery

Hemivertebra resection

On 20th May, we managed to observe four operations. Prof Hu operated the first case, 56-year-old female with multilevel degenerated cervical spondylosis and PID C3-C6, treated by C5 corpectomy with cage and anterior ACDF C3-4. Another cervical PID C4-7 was operated by the same technique. The cervical was almost straight in these two cases and anterior approach was treatment of choice. The third case that we observed was early onset scoliosis treated by hemivertebra resection and fusion. We were impressed by decision making for operation and surgical skill of Prof Zhaung, a national reputation and well-known scoliosis surgeon.



Corpectomy and ACDF for CSM

On 21st May, Thursday morning conference, discussion on problematic cases presented by residents, experienced surgeons from interdisciplinary departments gave comments and planned for further management. Dr Kyaw Min, had a chance to present a paper about treatment of spinal tuberculosis in Myanmar. We got healthy and fruitful discussion from many experienced surgeons.



Morning conference and presentation

Furthermore 2015 PUMCH Scoliosis Research Society seminar on scoliosis treatment resulted in a very interesting event, where both, the local and the traveling fellows, gave presentations and exchanged ideas about the latest treatment of scoliosis such as role of magnetically controlled growing rods (MCGR) in the treatment of EOS. Prof Zhaung presented his case series of EOS treatment in PUMCH and concluded with some recommendation for EOS. If the scoliosis curve is short, he recommended osteotomy and fusion as the earlier, the better. In moderate scoliosis curve with involvement of 6 or 7 vertebrae, epiphysiodesis was treatment of choice before 5 year of age. If the curve is long, non-fusion technique with growing rod is an option but age at initial presentation must be balanced between efficacy and complication.



2015 PUMCH scoliosis research society seminar

During our stay in Beijing, we certainly enjoyed the city life on weekends and free time. We had the opportunity to visit various tourist attractions such as Great Wall, Forbidden City and Summer Palace.

The food was delicious and there were restaurants of all types to suit everyone's palate.

Second Centre: Taiwan

Date: 5/25/15 to 5/31/15

Venue: Chang Gung Memorial Hospital, Taipei

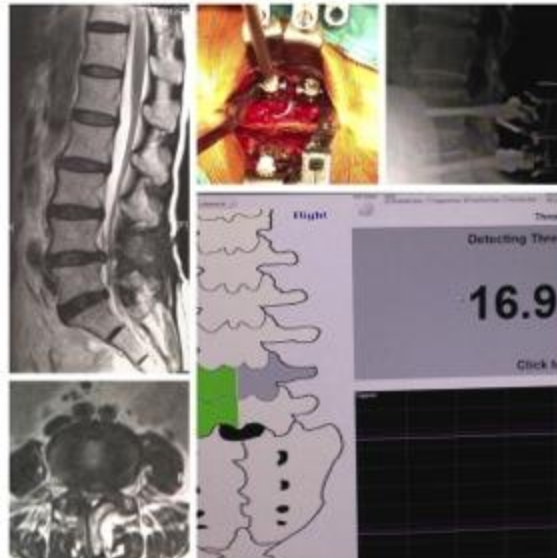
Host: Wen Jer Chen, MD

It was sad to leave Beijing, but Taipei gave us a warm welcome. The hospitality of Prof Chen has been amazing and the local spine team made us feel at home for all of our stay with them. Chang Gung Memorial hospital was 3000 bedded hospital including 200 bedded for orthopaedic. There were ten spine surgeons operating daily in five operating rooms. Approximately 200 cases of spine were operated by month.



Chang Gung Memorial Hospital

On 25th May, we were taken to spine unit where Prof Chen presented some fascinating case histories and radiograph. We had observed three degenerated lumbar spinal stenosis cases treated with multiple transforaminal lumbar interbody fusion procedure (TLIF). The life expectancy of Taiwanese population was increased and spine surgeons in Taiwan faced many degenerated spinal disorders. Prof Chen emphasized the advantages of TLIF in spinal decompression and maintaining the lumbar spinal lordosis.

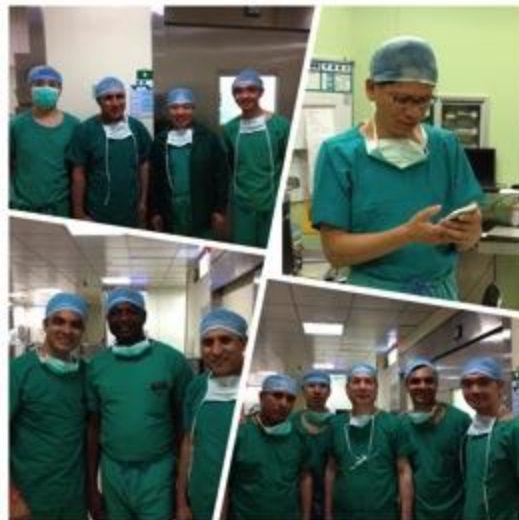

TLIF surgery and neuro-monitoring

On 26th May, three cases were lined up in the operation list. The first case was L1 compressed fracture due to secondary metastasis, which was treated by posterior decompression and instrumentation by pedicle screws and rods two levels above

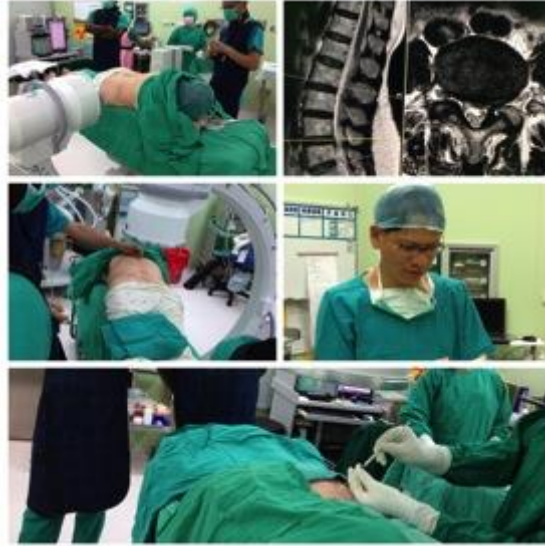and below. The second case was spondylolisthesis L4 over L5 (grade III) which was reduced and operated by TLIF procedure. Using EMG in every instrumented case impressed us so much. It is safe for patient and surgeon as well in case of medico legal issue. The last case, we observed, was PID C5-6. This case was operated by one of the 2014 APSS traveling fellow by ACDF. It was a great time to discuss with him about the case and traveling experience.

We were particularly impressed with the two early morning weekly meetings for the whole department of surgery. One of them was to discuss departmental surgical research, case presentations and to review the latest surgical development; and the other was morbidity and mortality meeting, which was compulsory for all members of surgical staff.



Spine team

On 27th May, there was morbidity meeting discussing about dural tear. This case was presented by one of the residents including brief history and evidence base literature reviews. This is part of the teaching for residents and the professors moderated the discussion and asked questions to all residents to get involved. The discussion was very impressed and fruitful to us. After that we went to operation theatre because there were four cases to operate. Dr Paul operated PID L4-5 by MIS using tubular retractor, which was new to us. Prof Chen explained about the accidental finding of vertebra haemangioma in degenerated lumbar spinal stenosis. He operated this case as usual TLIF procedure and forgot about the haemangioma. Dr Paul treated one L2-3 lumbar discitis case with anterior retroperitoneal decompression and posterior pedicle fixation. It looked like the tuberculous spine but it was rare in Taiwan and they thought it might be bacteria infection. We had a chance to observe nerve block using C arm guided by transforaminal approach.



Transforaminal lumbar nerve block

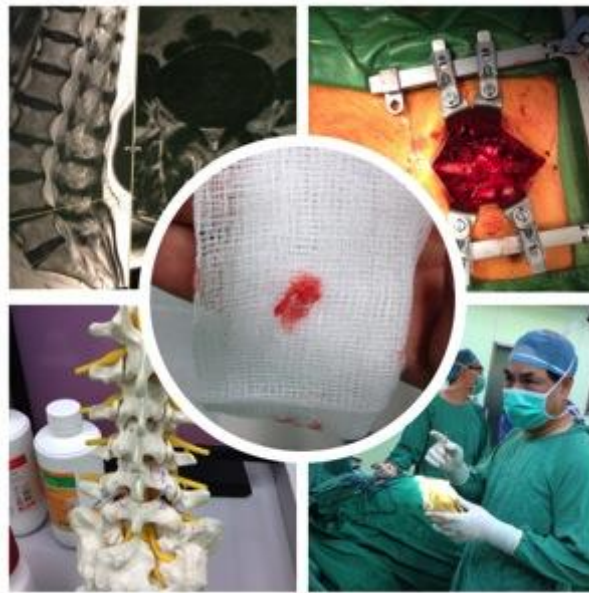On 28th May, another impressive weekly conference started on 7 am. The interesting cases from different spine units were presented and discussed by professors and senior surgeons. One cervical spine case was treated by anterior discectomy and bone grafting without plating. Three months later, this case was complicated with graft failure and cervical kyphosis. We discussed about the causes and further management plan. It was a delight to hear the experience of senior surgeons. We had observed three interesting cases at operation theatre. Polio patient with scoliosis was revised 14 times by repeated instrumentation due to rod broken and screws loosening. The insurance system covers the cost for this patient. Another case was adjacent segment degeneration, which they encounter most 5 to 10 years after instrumentation. The original implant was removed and adjacent segment was treated by TLIF procedure. The last case was multilevel degenerated spinal stenosis, which was managed by TLIF procedure as well.



Mortality and morbidity meeting

On 29th May, four cases were lined up for Prof Chung. Apart from one case of spondylolisthesis, the remaining three were degenerated spinal stenosis. Among the degenerated cases, we encounter one case of gouty tophi deposits in PLL and ligamentum flavum. Prof Chung showed the deposits to us and said it was common in Taiwanese people. He already had one paper published in European journal about this pathology.

Prof Chan and his spine team hosted the dinner at Fullon hospital with great and delicious food. We visited to Taipei 101 building, which currently 4th tallest building in the world. We enjoyed the breathtaking scenery of National museum.



Gouty tophi deposit at PLL

Third Centre: Hong Kong

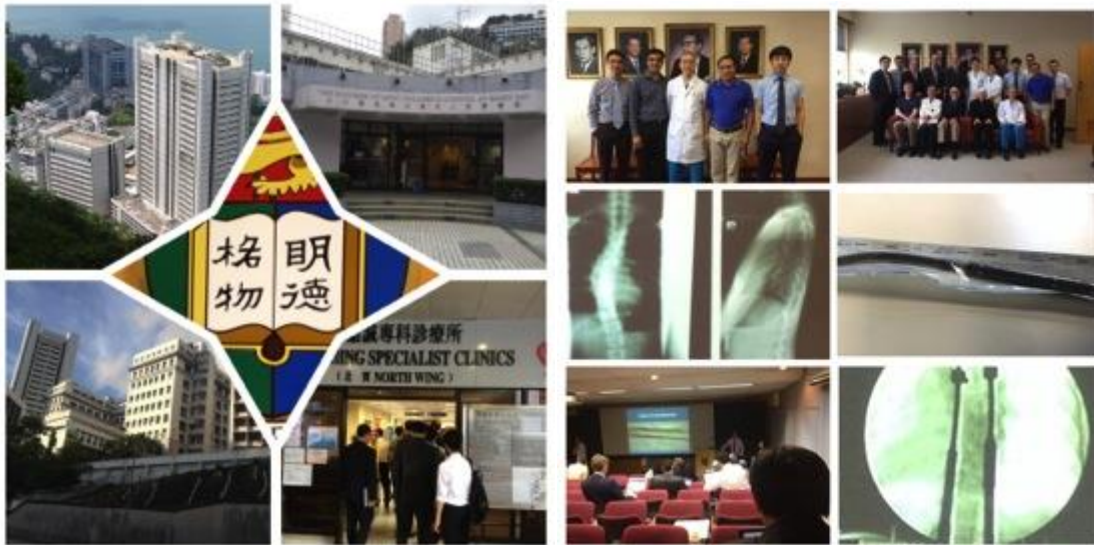
Date: 6/1/15 to 6/7/15

Venue: Queen Mary Hospital, Hong Kong

Host: Kenneth Cheung, FRCS

We spent our last week of fellowship visiting to Hong Kong. It was a big dream of mine to visit this beautiful island. We were greeted and welcome by Professor Cheung, Head of Spine Department at Queen Mary Hospital, who was so energetically and eager to take and give the best of himself in every moment of the day. It is 1700 bedded tertiary referral hospital for the whole territory of Hong Kong and beyond, Q M hospital main ward tower is the tallest hospital building in ASIA

and third tallest in the world beyond London's Guy's hospital and Houston's O'Quinn Medical Tower at St. Luke's hospital. Many photos of international reputation surgeons who had visited to this hospital and given lectures amazed us. We had a chance to observe Live surgery in Magec rod operated by Prof Kenneth Cheung and discussed by SRS surgeons. This kind of observation might be an excellent source of education young surgeons. Further scientific conference resulted in a very interesting afternoon, where both, the local and the traveling fellows, gave presentations and exchanged ideas.



Queen Mary Hospital

Magec rod Live surgery demonstration

On 2nd June, we started the day with a conference on combined scientific meeting at orthopaedic learning centre of Chinese University of Hong Kong. Prof J Cheng , first generation spine surgeon of hospital, gave a welcome speech. We were very pleased at the kindness and professionalism of him. We experienced a wonderful discussion about scoliosis by SRS (Scoliosis Research Society) members and participants from Chinese University of Hong Kong. Many new developments or valuable experience were presented and discussed. All were encouraged to ask questions and discuss something. We learned a lot from this. The afternoon was spent in visiting the Duchness of Kent's Children Hospital accompanied by Prof Luk. He guided tour of hospital, including the history and development.



Duchness of Kent Children Hospital at Sandy Bay

On 3rd June, we had a chance to attend the seminar on MAGEC Surgeon User Meeting at Cheung Kung Hai conference centre. Well known spine surgeons around the world, arouse the interest and awareness of deformity correction developments in the field of Myanmar Orthopaedic Society. The researcher gave us the tour of the lab; the lab was unique and immaculate. It was an all-in-one research center including capabilities for studies related to biomechanical engineering, cell biology, histopathology, microCT and computer modeling etc. Further evening program was very exciting and interesting presentations by international reputation scoliosis at Queen Mary Hospital. Discussion about complications of MAGEC rods and its cost effectiveness were very impressive. Although it is not currently available in developing country, we are now ready for using it once getting support from government.



MAGEC user meeting and research laboratory

On 4th June, the first day of 12th Hong Kong international orthopaedic forum (HKIOF) & 10th combined congress of the Asia Pacific Society (APSS) & The Asia Pacific Paediatric Orthopaedic Society (APPOS) 2015. It is SRS World Wide Course scientific programme on degenerated scoliosis and adolescent idiopathic scoliosis which resulted in very exciting and interesting afternoon. We learned about the guideline for prevention of proximal junctional kyphosis (PJK) in spinal fusion. It is worthy to note, never end lumbar fusion at L1, never end at coronal apex, never end at thoracic kyphosis apex and avoid denervation of proximal facet joints.




Hong Kong 2015 – Combined Congress

On 5th June, our group presentation about APSS traveling fellowship 2015 was a wonderful experience, and Dr Kyaw Min was honored to present on behalf of our group. Notable focused seminars include management of degenerated spinal deformity, spinal tumours, infection and trauma. There was a debate for treatment of cervical spondylotic myelopathy (CSM) whether approaching anteriorly or posteriorly. Prof Katsuji SHIMIZU concluded in his presentation as certain group of CSM (kyphosis, multiple disce lesion, OPLL, failed laminoplasty) should be treated anteriorly. On the other hand, Prof Wai Mun Yue from Singapore recommended laminoplasty in CSM even with cervical kyphosis of 10°, which was supported by Prof Kokubun from Japan. He said failure of laminoplasty leading to revision surgery was a rare occurrence.



APSS traveling fellow 2015 presentation

On 6th June, AOSpine Advanced symposium in spine fractures about uncommon scenarios of common spine injuries was very effective for spine surgeons around ASIA Pacific region. The expert panel discussion was very impressive as well. The presented cases were C1-2 fracture by Dr YK Chan, Osteoporotic L1 compressed fracture by Prof John Chen, multiple lumbar fractures by Prof Qiang Qi from China. We felt quite confident in spine fracture management after attending the fruitful panel discussion.



On 7th June, this is the last day of congress, the morning session started with free paper presentation on spinal trauma, infection and tumours. After that we had a very interesting Operative video session for deformity correction techniques such as vertebral column resection by Prof Chung Chek Wong, Lumbar pedicle subtraction osteotomy by Prof Li-Tack KIM, Posterior surgery for TB spine by Prof Arvind JAYASWAL, surgery for spinal metastasis by Prof Mun Keong KWAN and lumbosacral fixation by Prof John DIMAR. These narrated surgical demonstration by international experts are exciting program and to encourage knowledge exchange. This is the program we liked the most.



Exhibition

The evening program was an outstanding concert by residents of Chinese University of Hong Kong resulted in an unforgettable experience where we enjoyed good music, delicious dinner and friendship in one of the most amazing locations of the entire world.



Congress dinner

It is an interesting and valuable experience to get to know health system in Asia Pacific region. We learn procedures that will affect our practice in future and came back home with new energies and ideas, for sure. The friendship between all of us and our host is going to be a relationship for life. We look forward to seeing everyone in a future trip. We believe that this experience is something that has to be part of the life of all those young surgeons who are planning to have active roles in spine society.

Acknowledgement

- We are indebted to the APSS and Depuy Synthes for their generous travel grant, which made this fellowship possible.
- We would also like to give our gratitude to own centres for supporting us to avail such a fantastic learning opportunity.
- We are very much thankful to our hosts in Beijing, Taipei and Hong Kong. The hospitality in all centres has been beyond the expectations.
- All of this could not be possible without the help of Ms. Jenny Wong, the remarkable coordinator of this fellowship.

APSS Depuy Synthes Travelling Fellowship 2015 Logbook

No	Age	Sex	Diagnosis	Procedure	Surgeon	centre
1	72	M	Lumbar soinal stenosis	Posterior decompression and instrumentation	Prof Xui	PUMCH
2	21	M	Congenital thoracic scoliosis	Hemivertebractomy and posterior instrumentation	Prof Xui	PUMCH
3	13	F	Congenital thoracic scoliosis	Posterior instrumentation and fusion	Prof Zhaung	PUMCH
4	56	M	Operated scoliosis	Revision surgery	Prof Zhaung	PUMCH
5	62	M	Lumbar spinal stenosis	Decompression and instrumentation	Prof Zhaung	PUMCH
6	56	M	Cervical spondylosis C3-C6	C5 corpectomy and C3-4 ACDF	Prof Hu	PUMCH
7	55	M	Cervical spondylosis C4-C7	C5 corpectomy and C6-7 ACDF	Prof Hu	PUMCH
8	2 M	M	Congenital thoracic scoliosis	Hemivertebractomy and posterior instrumentation	Prof Zhaung	PUMCH
9	13	F	Thoracolumbar scoliosis	Long posterior instrumentation	Prof Xui	PUMCH
10	58	F	Operated discectomy and stenosis	TLIF	Prof Chen	Chang Gung Hospital
11	88	M	L1 compressed fracture	Posterior instrumentation	Prof Chen	Chang Gung Hospital
12	58	M	Spondylosthesis L4-5 with stenosis	TLIF	Prof Chen	Chang Gung Hospital
13	72	M	Multilevel stenosis with PID L4-5	Decompression and TLIF L4-5	Prof Chen	Chang Gung Hospital
14	79	M	PID L4-5	ACDF	Prof Chen	Chang Gung Hospital
15	49	F	PID L5S1	Discectomy	Dr Paul	Chang Gung Hospital

16	70	F	Spinal stenosis L4-5	Transforaminal nerve block L4-5	Prof Chen	Chang Gung Hospital
17	45	M	Infective spondylitis L2-3	Anterior decompression and posterior instrumentation	Dr Paul	Chang Gung Hospital
18	72	M	Spinal stenosis L4-5, L5S1	TLIF	Prof Chen	Chang Gung Hospital
19	55	M	Multilevel spinal stenosis	TLIF L2-3, L3-4, L4-5, L5-S1	Prof Chen	Chang Gung Hospital
20	56	M	Spondylolisthesis L4-5	TLIF	Prof Chen	Chang Gung Hospital
21	62	M	Operated spinal stenosis	Revision surgery TLIF	Prof Chen	Chang Gung Hospital
22	75	M	Spinal stenosis L1-S1	Multilevel TLIF	Dr Chen	Chang Gung Hospital
23	87	F	Spinal stenosis L2-S1	Posterior decompression and instrumentation	Dr Chen	Chang Gung Hospital
24	66	M	Spondylosthesis L4 over L5	TLIF	Dr Chen	Chang Gung Hospital
25	67	F	Spinal stenosis L4-5, L5S1	Posterior decompression and instrumentation	Dr Chen	Chang Gung Hospital
26	13	M	Congenital scoliosis	MAGEC rod	Prof Cheng	Queen Mary Hospital