

Asia Pacific Spine Society

Depuy-Synthes Clinical Fellowship Report

Period: 18th May – 7th June, 2015

.....

Fellow:

Dr. Najmus Sakeb

MBBS, MS(Ortho)

Consultant of Orthopaedic and Spine Surgery

Dhaka Community Medical College Hospital

Dhaka, Bangladesh.

Mentor:

Professor Ki-Tack Kim

Professor and Head

Department of Orthopaedic Surgery

Kyung Hee University Hospital at Gangdong

Seoul, South Korea.

&

President, Korean Association of Spine Surgeons

President, Korean Orthopaedic Society

.....

It is a great honor for me for being a recipient of the Asia Pacific Spine Society's (APSS) Depuy Synthes Clinical Fellowship program. I deeply pay my gratitude to the Society for arranging such a tremendous opportunity to learn from the maestros of Spine Surgery in this region. I can still feel my pounding heart while I received the mail from APSS with the confirmation of the Fellowship acceptance. My honored gratitude also goes to the selection committee for providing the chance to explore the new horizon.

This was my maiden journey to the east destined to Seoul, South Korea from Dhaka, Bangladesh. I reached almost midnight via a 5 hours stopover due to missed connection flight at Hong Kong International Airport (HKIA). Dr. Sang Pil HWANG fellow to Professor Ki-Tack KIM received me cordially and made all the necessary primary arrangements for my day to day needs, transportation and communication. The residence was arranged only 3 stations away along the subway-Purple line (Gil-Dong), which was 5 minutes to reach on foot from the hotel. There was no doubt that I felt like home even being 4000 KMs away from my country. I had a pleasant sleep before the commencement of the scheduled fellowship from 18th May 2015.

WEEK: 01 (18th -24th MAY 2015)

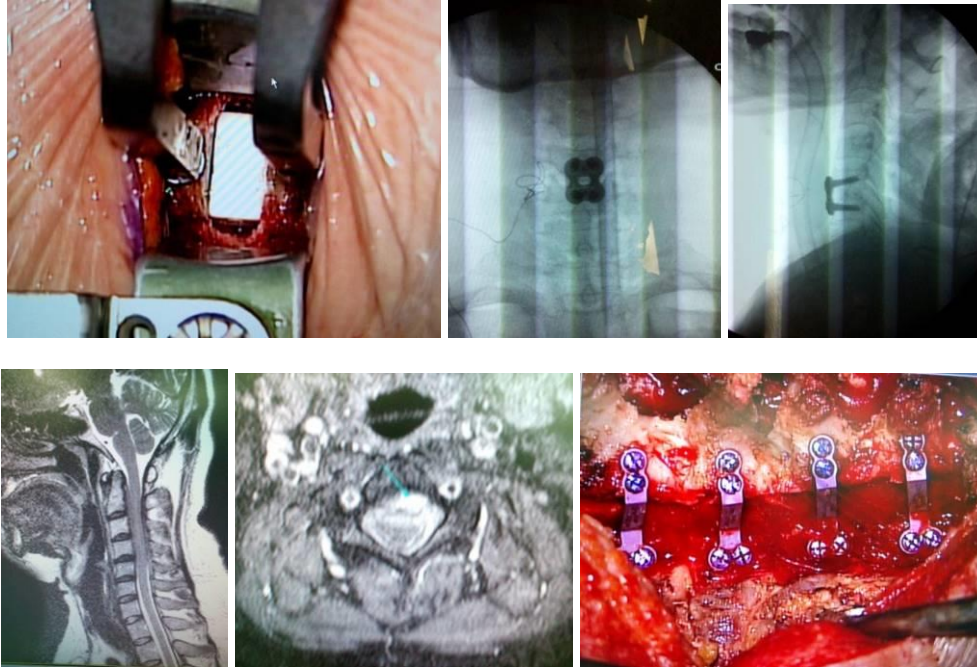
Monday, 18th May 2015 :

The fellowship started with introduction to the Department and University Spine Center. Professor Ki-Tack KIM received and introduced me to the department staffs. They were cordial to ensure my comfortable stay and the residents were kind and helpful to ensure the registration and enrollment process in the Hospital premises. As soon as the official procedures completed, I attended the Operation Theater with Professor Sang-Hun LEE.



The Kyung Hee University Hospital at Gang dong and the University Spine Center with Professor Ki-Tack KIM

The **first** case was a 79 years old lady presenting with old Spondylodiscitis L2/3 managed by ALIF L2/3 few years back, now suffering from Degenerative Retrolisthesis L3/4 with altered global balance and radiculopathy. It was the 2nd stage surgery where the 1st stage was already performed a week earlier by posterior decompression, release and instrumentation from D10 to S1. The Spine team has performed DLIF AT L4/5 and ALIF at L5/S1 through antero-lateral approach and extended the fixation upto ilium and stabilized posteriorly in the same sitting. The work was so delicate and synchronized to observe that I felt I am in the right place for my fellowship. The Spinal balance was restored properly with planned restoration of the lumbar lordosis. The **second** case was a 47 years old male having Herniated Cervical Disc with Right sided radiculopathy, who underwent Anterior cervical discectomy and Fusion (ACDF) with Cage and bonegraft with aid of the Microscope at C5/6 level. Professor Lee had been very much delicate in handling the patient till the end of surgery. His way of using the Burr makes the surgery very simple and rewarding for the patient. The **next** case was very interesting as a 37 year old male had been suffering from cervical stenotic myelo-radiculopathy at C2/3, C3/4, C4/5 for which he underwent Microscopic posterior decompression and laminoplasty C2-3-4-5. The **fourth** case was a 42 years male presented with C5 radiculopathy due to herniated cervical disc and underwent posterior Micro foraminotomy and Discectomy.



Surgeries observed (ACDF and Laminoplasty) on DAY-1 in Kyung Hee University Hospital at Gang Dong

After completing these scheduled surgeries we proceeded to three fluoroscopic procedures. The 45 year old female patient suffering from an acute episode of severe right sided radiculopathy of S1 due to Prolapsed Lumbar Intervertebral Disc (PLID) at L5/S1 not responding to conservative treatment underwent a Transforaminal Block (TFB). The following case was also similar in a 73 years old female at L4/5 and underwent TFB. The last case scheduled was a 70 years old female patient having degenerative spondylolisthesis with an acute episode of left sided symptoms non-responsive to conservative modes underwent a left side TFB at L4.

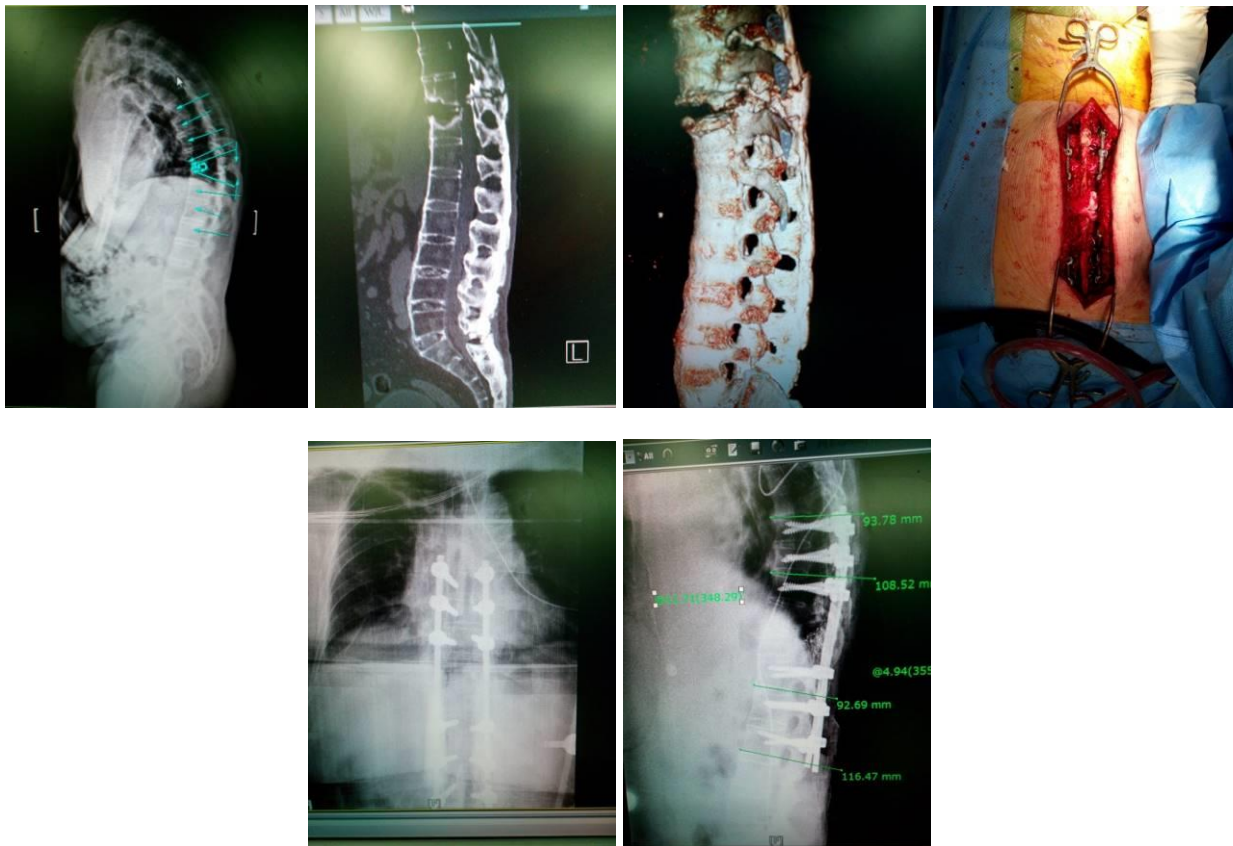Tuesday, 19th May 2015 :

It is the second day in Kyung Hee University Spine Center. Professor KIM has been so concerned with my stay and dining arrangements. It was really nice that he and his fellows were so kind to arrange the best possible amenities that I felt like home even in such a distant place with a completely new cultural environment. Today we had five scheduled cases for surgery. The **First** case was a 73 years lady suffering from degenerative flat back syndrome with altered sagittal balance and claudication symptoms was planned for first stage posterior release and instrumentation from D12 to S1. This was the first case for me where I had been taught to analyzing the images and planning the treatment of the patient depending on the parameters. To be honest, it was amazing for me to learn the science of calculating the goal for the patient. Professor KIM was so accurate with the osteotome and it looks fabulous. The 2nd stage surgery was left for next week. The **Second** case was a 63 years old lady suffering from Degenerative Spondylolisthesis L4 over L5 and Degenerative Lumbar Canal Stenosis (DLCS) L3/4 L4/5 which was decompressed with the aid of Microscope at L3/4 and Posterior Lumbar Interbody Fusion (PLIF) at L4/5. The **Next** case was Degenerative Spondylolisthesis (DSPLT) L5 over S1

managed by PLIF as before. The striking features in both these cases were the way Professor KIM decompressed the thecal sac. The **Fourth** case was a 53 year old male with recurrent PLID at L4/5 and underwent Microscopic revision discectomy. The **Final** scheduled case was a female of 78 years with Degenerative Lumbar Foraminal Stenosis (DLFS) with Radiculopathy and Instability at L5/S1 planned for a Unilateral Transforaminal lumbar Interbody Fusion (TLIF).

Wednesday, 20th May 2015 :

The day started with attending the Spine conference in the morning and there was a deliberate presentation and discussion on DSPLT and its management option and goals. After having the breakfast with the unit we straight away went for the Third consecutive theaters where we had three scheduled cases **starting** with a 75 year old female patient with DSPLT L3 over L4 and L4 over L5 with severe canal stenosis managed by 2 consecutive levels PLIF. The **last** case of the day was also a DSPLT L4 over L5 with severe canal stenosis and manages similarly with PLIF as well but the Microscopic decompression by Professor LEE was unique to observe. Other than these cases the **second** case was something unique and trademark of this Hospital; Ankylosing Spondylitis with Andersen lesion at D10/D11. Professor made space and went for wedge resection of the lesion and closing the wedge putting bone grafts in between and posterior fixation from D6 to L2. He is famous for his technical excellence in dealing with spinal osteotomies.



Anderssen Lesion at D10-11 managed by wedge resection and posterior stabilization

Thursday, 21st May 2015 :

Today was the first day of not being in the theaters but in the in patients. I attended the inter-department conference early in the morning where I was scheduled to be introduced. There were fruitful discussions regarding the surgeries with their postoperative follow-ups, diagnostic pitfalls, post-operative complications and their managements. We all had the breakfast together in the Hospital Canteen and went for the outpatient department (OPD). Professor KIM has a brilliant OPD staffs as he mentions them as the “QUEEN” of the Spine Center and certainly so they are. The time passed in the OPD very fast and at the end of the day its more than 50 patients tireless service. I had also observed the follow-up cases of previous surgeries. Thanks to the “Queen” as she managed everything accurate. Professor KIM arranged a dinner with the fellows and residents of the department with delicate Korean Cuisine. Definitely it was completely different in terms of taste and ingredients but there was no doubt that I enjoyed. I pay my gratitude to Dr. Sang Pil Hwang and Dr. Su Jin Jang for taking good care of me.



A glimpse of morning Spine conference and With Professor Ki-Tack KIM and the Chief of OPD Staff in the Out Patient Clinic

Friday, 22nd May 2015 :

I attended the morning Conference on Basic Orthopaedic Anatomy. I feel these very basic things are often very useful to memorize and pays tremendously during the surgeries. I had the breakfast with the fellows in the hospital premises and went for the last theater for this week. The **initial** case was a 75 year old man had history of ACDF at C5/6 had newer disc herniations at C3/4 and C4/5 with neurology on left. The case was managed by Laminoplasty C3-4-5-6 and microforaminotomy of C4/5 on left. The **second** case was 71 years old female with burst fracture D11with anterior wedging Causing Kyphosis. Professor KIM did the Pedicle Subtraction Osteotomy at D11 and instrumented posteriorly from D9 to L1. The **third** case was 71 year old male with post traumatic kyphosis at L3. PSO at L3 was performed with correction of the kyphosis and restoration of lumbar lordosis followed by posterior instrumentation D10 to Ilium. The **Final** case of the day was an infective spondyloarthropaathy D11-12 also managed by PSO and posterior instrumentation.

WEEKENDS (Exploring the Culture, Heritage and Cuisines)

Saturday to Monday, 23rd to 25th May 2015 :

SEOUL, The capital of the present day South Korea has long history of existence. It is the third most populous metropolis of the present world but extremely well organized and well connected with an extensive subway network system. It is said that 25 percent of the population of the country lives in Seoul and 50 percent of them are always in the extensive underground transportation. Its amazing to see the wide expressways with traffics but no logging on the roads. The city has been standing with pride even long before Christ but the Medieval Palaces from the 12th Century describes the elegance of the Hans in the region. I planned to explore the historical palaces in the long weekend and certainly so these places had been waiting with extraordinary experience for me. With a coincidence I met with the APSS travelling fellows of Group-II in front of the Secret garden of the Cheon Deok Gun Palace. We had a great time and had lunch together in full stomach!!!! Thanks to Dr Min Han ZAW of Myanmar for his excellent choices.

The next day the destination was the North Seoul tower; which can be availed by riding the cable car instead I choose to walk up the hill and as it always happens with an amateur- I started breathing short. While reaching at the top almost 1800 meters all the tiredness went away seeing the weekly cultural event; really fascinating one!!! I felt that Day to be an ideal one for visiting Itaewoon- the hub of international cuisines including continental, sub-continental, Arabic, Japanese, Chinese and Western foods. I tasted a Turkish cuisine which was really delicious. In the evening it was time for the Han River cruise and taking the fresh air along its banks. The way Seoulites have structured the shores are spectacular for cycling, skating, running, swimming and even if you want to enjoy concerts or cultural events. There is no doubt that the bank of the Han River is a masterpiece of Urban Recreation!!!

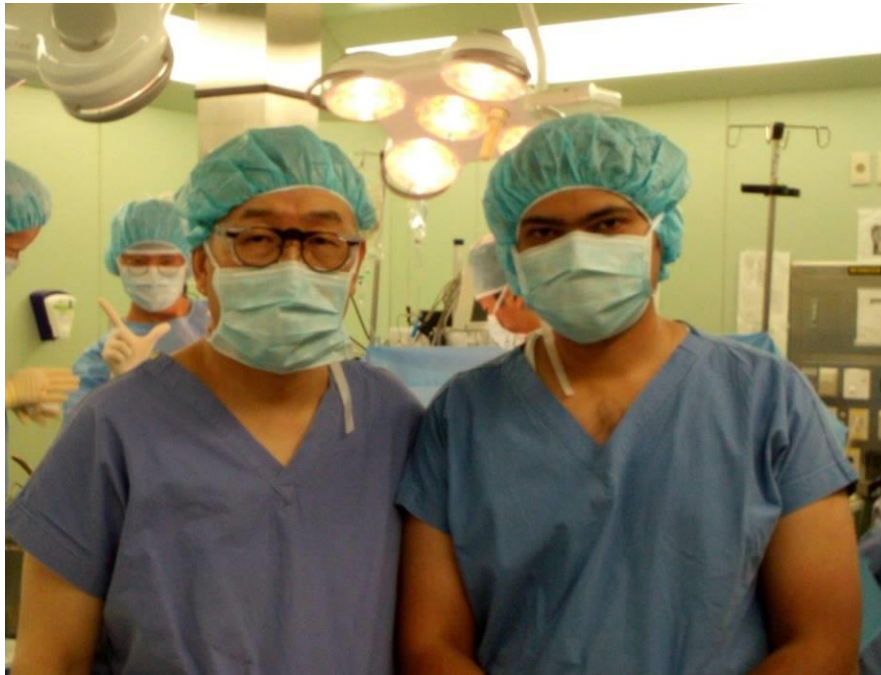

In front of Gyeongbok-gung Palace, with APSS Travelling Fellows and at the North Seoul Tower

WEEK: 02 (26th -31st MAY 2015)

Tuesday, 26th May 2015 :

The *first* case was the second stage surgery of the case that had been operated last week with posterior release and instrumentations. Professor KIM described the technique of Direct Lateral Interbody Fusion (DLIF) and the way he deals with the L4/5 and L5/S1 space during the procedure. He explained the role of CT Angiogram in the planning and procedure. I followed deliberately the way he positions the patient and checked all the additional. The Hockey stick incision makes the approach to L5/S1 space more convenient to deal with. The surgery was very meticulous with his expert team members and they completed the surgery without any difficulty. They did DLIF at L2/3, L3/4, L4/5 and L5/S1 and rotated the patient for the posterior procedure. The posterior fixation was done after decompressing the required levels. Professor KIM did the Partial Pedicle Subtraction Osteotomy (PPSO) at one level to achieve the required lordosis and the fixation was extended to the Ilium as well. The *following* case was a 68 years old lady with DSPLT L4 over L5 which was managed by PLIF. I scrubbed in the case and assisted Professor KIM in the procedure. The technique of dealing with the lamina was something different from the others. He is comfortable with wide decompression of the thecal sac and the nerve roots that makes the patient symptom free. The *third* case was also a Degenerative Flat Back Syndrome in a 68 years lady. She was planned for the first stage surgery that day. I scrubbed in the case and assisted the posterior decompression and instrumentation from D12 to S1. This case would undergo the second stage surgery next week again. The *last* case was DLCS L3/4, L4/5 with DLFS L4/5 on the right side. I was also allowed to scrub in the case where Professor performed posterior decompression and unilateral TLIF.



With Professor Ki-Tack KIM in the theater

Wednesday, 27th May 2015 :

There were only two cases for the day and I scrubbed in both cases assisting Professor KIM. He is a great and generous teacher for teaching the surgical tips in every procedure. The *first* case was a 73 years female with Bilateral DLFS L3/4, L4/5 with radiculopathy managed by PLIF L3/4, L4/5. The *following* case was a 56 years male suffering from the similar pathology and was also treated with the same procedure.

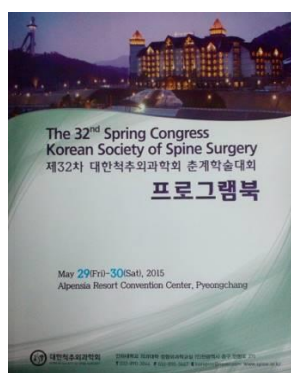
Thursday, 28th May 2015 :

As the previous week schedule the day started with the inter-department conference where there is always a brief discussion of the week's activity. After the conference we had the breakfast together and went for the ward rounds. I observed the inpatient management of the cases as well as the follow-up condition of the patients operated this week. I went with the Fellows to their office just opposite to the road, where they study and spent few hours with them. I went through the recent editions of the Spine surgery texts and discussed with them as well. In the afternoon there was a lecture schedule after which all the residents and fellows were invited to a Barbecue Dinner in a local posh restaurant just outskirts of the neighborhood. We had great fun with all the attendees with Barbecues in front. The week in Seoul ended that day because we were scheduled to pack up for the upcoming conference of the Korean Society of Spine Surgery in Pyeong Chang- 3 hours drive south east to SEOUL.

Friday to Sunday, 29th to 31st May 2015 :

32nd Spring Congress of Korean Society of Spine Surgery

The 32nd conference had been scheduled in Alpensia Resort Convention Center, Pyeong Chang- the city for the winter Olympics for 2018. It is almost 250 Kms drive from Seoul along the highways through the mountainous landscape. The two fellows Dr. Sang Pil Hwang and Dr. Su Jin Jang took the long drive for me. It was an amazing drive with them to reach the venue at almost 2 AM. (I can never forget the baseball experience in dire midnight under the argon lights at a midway stopover!!!).



The 32nd Spring Conference with Dr. Hwang and Dr. Jang

The Alpensia Resort is an amazing place surrounded by mountain courses for skiing. The conference was also amazing like the resort! The first day covered the lumbar spine, Spine trauma, Osteoporosis and Minimally Invasive Spine Surgery (MISS). I met Professor Arvind Jayaswal and we had a short sightseeing of Pyeong Chang range at the end of Day-1. It was marvelous to see the blend of nature and use of modern technology in harvesting. We explored a 16th century Buddha temple which has a background history of being burnt down during the Korea-Japan war. Professor Ki-Tack KIM arranged a grand dinner that night with all the residents and Spine department staffs. We enjoyed the dinner almost 150 kms east from the venue by the shore of the East Sea (Sea of Japan) with fresh sea food menu. I was really amazed with the culture, food and hospitality in the Korean way. Definitely it was a lifetime experience!!



With Professor Ki-Tack KIM, Professor Arvind Jayaswal and Professor Sang-hun LEE



Exploring Peyong Chang Neighborhood with Professor Arvind Jayaswal, The East Sea on the backdrop and delicious Korean seafood absolutely fresh!!

The second and the last day of the conference focused on cervical spine and spinal deformity. It was really fascinating to see the extent of work that has been performed by the Korean Spine Surgeons. The Scientific papers were unique in terms of focusing each issue deliberately. The presentations on the spinal deformities were excellent regarding the outcomes. Professor KIM arranged a full fish lunch in the neighborhood for all the unit staffs, doctors and residents. The

menu was delicious and I found some similarities with sub continental style cuisine blended with traditional Korean side menus.

The day did not end with the lunch as because we were planned to drive another 150 KMs South-west to Wong Ju, where there was scheduled meeting in the Marvelous Golf Course with all the past fellows of Professor KIM. It was an experience that I will remember life time. All the fellows came there and presented the interesting cases and how they managed. There were discussions of procedures and techniques for being more accurate and beneficial for the patients. Professor LEE had a lecture on the updates of Central Cord Syndrome and their managements. Completing all these events with light refreshments we were destined to attend a grand dinner where Professor KIM delivered speech for the fellows. I was amazed to see and feel that how everyone respected him for his contributions. The day was definitely a red calendar day, an unforgettable dinner with Professor KIM and his Fellows.

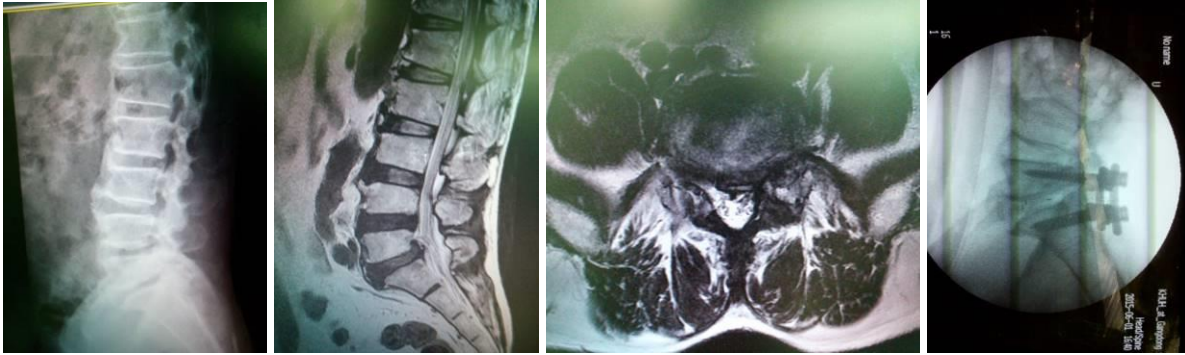

The fellows gather yearly and discuss the experience with Professor Ki-Tack KIM

WEEK: 03 (1st -7th June 2015)

Monday, 1st June 2015 :

After long three days of conferences, congregations and long distance travels we were again in the theaters and today it was with Professor LEE. Out of the three scheduled cases **First** case was a 50 years male diagnosed as Ossified Posterior Longitudinal Ligament (OPLL) from C4 to C7 with myelopathy was managed by Laminoplasty C3-4-5-6. The technique of Microscopic decompression is very safe and meticulous. Professor described the pathology and showed the technical aspects of the images after the procedure. The **following** case was 73 years female with DDD and DLCS L3/4, L4/5 with right sided radiculopathy. Professor LEE did microscopic decompression of both the levels and discectomies. The **last** case of the day was a male patient of 67 years suffering from Degenerative left sided foraminal Stenosis at L5/S1 level with radiculopathy managed by PLIF at L5/S1. I scrubbed in the last two cases to assist.



A case with Degenerative Foraminal Stenosis L5/S1 with Right sided Radiculopathy managed by PLIF

Tuesday, 2nd June 2015 :

I had a very busy day and incidentally this was to be the last day in Kyung Hee University Hospital. Out of the four cases for the days list the theater *started* with the second stage surgery of the 68 year old woman who underwent Posterior release and instrumentation from D10 to S1 due to degenerative flat back syndrome. Professor KIM did the Direct Lateral Interbody Fusion (DLIF) L3/4 and Anterior Lumbar Interbody Fusion (ALIF) L4/5 L5/S1. The surgery looked so simple in his hand. Professor described the technical aspect of the procedure and the importance of approaching the spine through this approach. Turning the patient prone posterior instrumentations were extended upto ilium. The *second* case was a 72 years female with failed surgery syndrome (PLIF L2-5) planned for a staged revision surgery. Today it was the first stage where all the posterior implants were removed and unilateral TLIF was done at L1/2 and an extensive posterior release was done from D12 to S1. The second stage surgery was left for the next week. The *following* case was a revised case of PLIF L3/4 with extension of Fusion upto S1 but having a persistent dural leak. The wound was re-explored and the leak was identified and sutured with keeping a lumbar drain insitu. The *last* case of the day was a 67 years old lady with degenerative lumbar canal stenosis L3-S1 with degenerative foraminal stenosis L5/S1 underwent decompression L3-S1 with spinous process splitting approach. This was another interesting technique of decompression that was really fantastic to learn.

After the theaters, we all moved to the seminar hall, where I had presented my scheduled lecture on “correlation of the lumbo-pelvic parameters and clinical results of single level TLIF in low grade degenerative Spondylolisthesis-1 year follow-up results”. We had a group photo-shoot after the presentation. Professor KIM and Professor LEE had invited his fellows and me to the Grand dinner with an Exquisite Japanese Sushi in a very famous Japanese Restaurant. Undoubtedly delightful way of presentation of the Japanese Sea Food Cuisine was even more tasteful to enjoy as Dinner. The fellows arranged a farewell coffee and it was time to say Good Bye to all of them.

Wednesday, 3rd June 2015 :

The flight to Hong Kong was scheduled to depart at 10 AM. I checked out early in the dawn and availed the airport shuttle bus. Along the course of the Han River the bus was heading to the Incheon International Airport. The amazing landscape of Seoul was blended with modern High Risers and Multiple Bridges connecting the both banks of the river. The wide roads with modern Korean cars were very nice to see. I reached the airport in time and crossed the immigration to board the plane but it was the memories of the last few weeks that were mostly remembered. It was a great time for me to observe, assist and learn as well as to make new friends and experience the culture and heritage of Korea.

The flight departed on time and after about 3 hours around 1:30 afternoon it landed at Hong Kong International Airport, Lantau, Hong Kong- A beautiful Airport within a mountainous Island. The journey was smooth although there was a developing health concern due to a recent MARS outbreak. I took the Airport Express Rail and reached the Hong Kong Subway Station, from where I took the Blue line for 2 stations to Tsai Yin Pun and reached the destination to Best Western Hotel Hong Kong, where all arrangements were made for stay.

[Pre-Meeting SRS Course and The Combined Congress of 12th Hong Kong International Orthopaedic Forum (HKIOF) & 10th Asia Pacific Spine Society (APSS) & Asia Pacific Paediatric Orthopaedic Society (APPOS)]

Thursday to Sunday, 4th to 7th June 2015 :

The activities in Hong Kong started with the Scoliosis Research Society Pre Meeting Course on Thursday. I reached the amazing convention center by the Victoria Harbor taking the subway 3 stations away from our hotel. The course speakers were very particulate regarding the Scoliosis Issue. The lectures were precise regarding the Sagittal Balance issue in Adult Degenerative Scoliosis as well as recent debates and discussions regarding Adolescent Scoliosis.

The next morning started with the presentation of the fellows including me. It was my great honor to represent Bangladesh. It's beyond doubt that APSS has arranged a big platform for the young surgeons to build themselves for a brighter future. I have attended the later rapid fire sessions and the sessions for degeneration, tumors and infection where there were fruitful discussions regarding practical issues.



Golden Bauhaniya Square from the conference Hall and my presentation session

The third day of the conference was focused on degenerative spine, paediatric and adult spinal deformity. The presentations were enriched with information regarding surgeries from open to MIS, placing screws from cervical to ilium, and even every sort of degenerative spine problems and deformity issues for paediatric and adults were addressed. At the end of the day the Congress Banquette included handing over the certificates. Professor Kuniyoshi Abumi and Professor Arvind Jayaswal handed over the recognition one by one to all the fellows. Certainly it was a big big day!

The next day was the last day of the conference and the last day in Hong Kong as well. But the conference stored the operative video session for that day, certainly Professor Chung Check Wong, Professor Ki-Tack Kim, Professor Arvind Jayaswal, Professor Kuniyoshi Abumi, Professor Mun Keong Kwan and Professor John Dimar had set the buzz with their excellent demonstration of the surgical techniques.



With Professor Kuniyoshi Abumi (and Dr SI Akon) and Professor Mun Keong Kwan



The 2015 APSS Fellows with Depuy Synthes Officials

My 3 weeks spent in Kyung Hee University Hospital, Seoul, South Korea, with Professor Ki-Tack Kim and his brilliant Spine department had been full of excellent memories of fantastic surgical exposure and patient management. My heartiest gratitude goes to Professor Ki-Tack KIM for his marvelous arrangement for my stay and privileges in the theater for a greater and wider exposure to the surgical techniques and to convey the pros and cons of management.

I would like to thank Asia Pacific Spine Society (APSS) – the Spine Section of Asia Pacific Orthopaedic Association (APOA) for providing the great opportunity to explore the new horizon. I also want to thank the Selection committee for selecting me for the fellowship. My deepest gratitude goes to Professor Arvind Jayaswal, Professor Mun Keong Kwan and Professor Chris Chan Yin Wei for helping me to make things possible. It's praiseworthy to mention Mrs Jenny Wong- who had been communicating even in her personal times to coordinate in the best possible way for a flawless completion of the fellowship.

Logbook Entries

Date/ Day	No	Age	Sex	Diagnosis	Surgery	role
18.05.2015 Monday	01	79y	M	Degenerative Retrolisthesis L3/4 with altered global balance and radiculopathy with L2/3 fused state (ALIF)	2 nd Stage ALIF L4/5,L5/S1 and Posterior decompression and fixation	Obs
	02	47y	F	Herniated Cervical Disc C5/6 (R)	ACDF C5/6	Obs
	03	37y	M	Cervical Stenotic Myelo-Radiculopathy at C2/3, C3/4, C4/5	Laminoplasty C2-3-4-5	Obs
	04	42y	M	Herniated Cervical Disc C4/5(Foraminal disc) (R)	MicroForamimnotomyC4/5	Obs
	05	45y	F	PLID L5/S1	Transforaminal Block	Obs
	06	70y	F	PLID L4/5	Transforaminal Block	Obs
	07	73y	F	Degenerative Spondylolisthesis L4-L5	Transforaminal Block	Obs
19.05.2015 Tuesday	08	73y	F	Degenerative flat back syndrome (DFBS) with altered sagittal balance and claudication	1 st stage posterior release & instrumentation D12-S1	Obs
	09	63y	M	Degenerative Spondylolisthesis L4 -L5 and Degenerative Lumbar Canal Stenosis (DLCS) L3/4 L4/5	Microscopic Posterior decompression at L3/4 and PLIF at L4/5	Obs
	10	66y	F	Degenerative Spondylolisthesis L5-S1	PLIF L5/S1	Obs
	11	53y	M	Recurrent PLID L4/5 (L)	Revision Microdiscectomy	Obs
	12	78y	F	Degenerative Lumbar Foraminal Stenosis (DLFS)L5/S1(R)	Unilateral TLIF L5.S1	Obs
20.05.2015 Wednesday	13	75y	F	Degenerative Spondylolisthesis L3-L4,L4-L5	PLIF L3/4.L4/5	Obs
	14	71y	M	Ankylosing Spondylitis with Andersen lesion at D10/D11	Wedge osteotomy with posterior fixation D6 to L2	Obs
	15	72y	F	Degenerative Spondylolisthesis L4 -L5 with Severe Canal Stenosis	Posterior MicroDecompression & PLIF L4/5	Obs
22.05.2015 Friday	16	75y	M	Herniated Cervical Disc C3/4 and C4/5 (L) with ACDF C5/6 state	Laminoplasty C3-4-5-6 and microforaminotomyC4/5(L)	Obs
	17	71y	F	Burst Fracture D11with Kyphosis	PSO D11 and posterior instrumentation D9-L1	Obs
	18	71y	M	Post traumatic Kyphosis L3	PSO L3 and posterior instrumentation D10-Ilium	Obs
	19	78y	M	Infective Spondyloarthropaathy D11-12	PSO D12 and posterior instrumentation D10-L2	Obs
26.05.2015 Tuesday	20	73y	F	Degenerative flat back syndrome (DFBS) with 1 st stage release & instrumentation D12-S1	2 nd Stage DLIF L2/3, L3/4, L4/5 and ALIF L5/S1 & Posterior fixation to Ilium	Obs
	21	68y	F	Degenerative Spondylolisthesis L4 -L5	PLIF L4/5	Asst
	22	68y	F	Degenerative Flat Back Syndrome (DFBS)	1 st Stage posterior release & instrumentation D12-S1	Asst
	23	76y	M	DLCS L3/4, L4/5 with Degenerative Lumbar Foraminal Stenosis (DLFS) L4/5 (R)	Posterior MicroDecompression L3/4, Uni-TLIF L4/5	Asst
27.05.2015 Wednesday	24	71y	F	Bilateral DLFS L3/4, L4/5	PLIF L3/4.L4/5	Asst
	25	56y	M	Bilateral DLFS L3/4, L4/5	PLIF L3/4.L4/5	Asst
01.06.2015 Monday	26	50y	M	Ossified Posterior Longitudinal Ligament (OPLL) C4-C7 with myelopathy	Laminoplasty C3-4-5-6	Obs
	27	73y	F	Degenerative Disc Disease&DLCS L3/4, L4/5 (R)	Microdiscectomy L3/4,L4/5	Asst
	28	63y	M	DLFS L5/S1(L)	PLIF L5/S1	Asst
02.06.2015 Tuesday	29	68y	F	Degenerative Flat Back Syndrome (DFBS) with 1 st Stage posterior release and instrumentation from D12-S1	2 nd Stage DLIF L3/4, ALIF L4/5,L5/S1 and Posterior fixation to Ilium	Asst
	30	72y	F	Failed Back Surgery Syndrome (FBSS) with L2-5 Fusion State	1 st Stage implant removal, TLIF L1/2, Posterior release & instrumentation D12-S1	Obs
	31	70y	F	PLIF I3/4 with rod extension L3-S1 & dural tear	Insertion of Lumbar drain	Obs
	32	67y	F	DLCS L3/4, L4/5, L5/S1 with Degenerative Lumbar Foraminal Stenosis (DLFS) L5/S1 (L)	Simple Decompression L3/4/L4/5,L5/S1	Obs